



Grafting and Dental Implantation in Patients With Jawbone Cavitation: Case Series and 3-Year Follow-Up

Ya-Wei Chen, DDS,* Miguel Simancas-Pallares, DMD,† Mauro Marincola, DDS,†
and Sung-Kiang Chuang, DMD, MD, DMSc‡

Dental implantation is considered to be a predictable treatment modality for restoration of missing teeth. A satisfactory outcome should be achieved, if all of the following factors, including a comprehensive review of systemic and anatomical conditions, thorough treatment plans, and well-performed surgical procedures, have been taken into consideration. However, one of the intraoperative complications, displacement or migration of implants, may sometimes occur unpredictably. The most common situation is an accidental displacement of endosseous implants into maxillary sinus,¹ while such complications associated with mandible rarely happens. Nevertheless, some cases have been reported in which mandibular implants were found with loss of cortical bone engagement and displaced into marrow space of lower jawbones.^{2–5} Primary stability is compromised as a result of implant

Purpose: *Jawbone cavitation (BC) is not uncommon and is considered to be related to some cases of unexpected implant displacement into deep jawbone space. Here, a series of cases with BC is described, in which the lesions were accidentally found and successfully treated by bone grafting and dental implantation.*

Methods: *Thirty-four partially edentulous patients who were found to have BC during dental implant surgeries were included in this study. Alloplast bone substitute (β -tricalcium phosphate) grafting with immediate or staged locking-taper implant placement was performed. Bone filling and implants on BC were followed up to 36 months, and they were evaluated clinically and radiographically to verify treatment outcome.*

Results: *A total of 41 BCs were found at premolar and molar regions, which involved one or more teeth breadth. Nearly most of the lesions occurred in the mandible (95.1%, 39/41). Histologically, they were compatible with focal osteoporotic marrow defects. Fifty-two locking-taper implants and final restorations were delivered on 38 BCs. One implant failed due to loss of integration. The overall cumulative 3-year implant survival rate was 98.1%.*

Conclusion: *By carefully examining and managing the surgical bed, the current treatment modality was shown to yield a satisfactory outcome for restoration of edentulous ridge with underneath BC. (Implant Dent 2017;26:158–164)*

Key Words: *bone graft, cavitation, dental implant, jawbone, osteoporosis*

*Attending Surgeon and Assistant Professor, Oral and Maxillofacial Surgery, Department of Stomatology, Taipei Veterans General Hospital and School of Dentistry; and National Yang-Ming University, Taipei, Taiwan. Research Fellow, Department of Oral and Maxillofacial Surgery, Massachusetts General Hospital and Harvard School of Dental Medicine, Boston, MA.

†Faculty, Dental Implant Unit and Research Department, Faculty of Dentistry, University of Cartagena, Cartagena, Colombia.

‡Oral and Maxillofacial Surgeon, Good Samaritan Medical Center, Brockton Oral and Maxillofacial Surgery, Inc., Brockton, MA.

Reprint requests and correspondence to: Sung-Kiang Chuang, DMD, MD, DMSc, P.O. Box 67376, Chestnut Hill Station, Chestnut Hill, MA 02467, Phone: +1-617-527-4981, E-mail: sungkiangchuang@gmail.com

ISSN 1056-6163/17/02601-158

Implant Dentistry

Volume 26 • Number 1

Copyright © 2016 Wolters Kluwer Health, Inc. All rights reserved.

DOI: 10.1097/ID.0000000000000558

overloading, insufficient bone quantity, or poor bone quality (eg, low density of trabecular bone, thinness of cortical bone, osteopenia, or osteoporosis).^{3,6}

Jawbone cavitation (BC) or osteocavitation is an anatomical phenomenal term, which has been used to describe the result of a disease process in which lack of blood supply to an area of bone resulted in a hole or hollowed-out space in the jaw. Tracing back to history, this kind of jawbone lesion

was first described in the early 1870s by Noel. He depicted the noticeable defects in jawbone and considered them as a reason of dead or reduced vitality of bones.⁷ In 1915, Black⁸ proposed possible causes and clinical findings of these cavitations. He found that although there were large destroyed areas within the jawbones, seldom did they cause pain, redness on the gingiva, swelling of the jaw, or rise in body temperature. Now various entities of diseases have been linked to

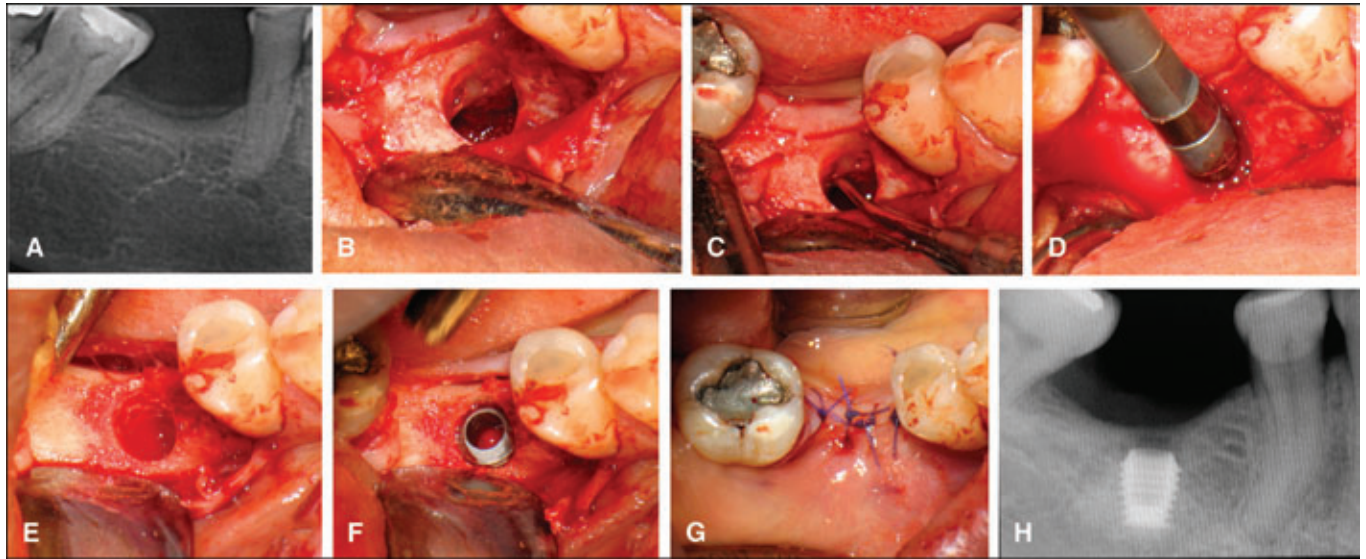


Fig. 1. Example of a case in which simultaneous bone grafting and implant placement was performed in 1 visit. **A**, Dental radiography of the edentulous region shows a 2- to 3-mm thick cortical bone. In the cancellous region, gross bone density seems normal, but some indistinct trabecular rarefaction can be noticed after careful inspection. **B**, After flap elevation and osteotomy made for surgical bed preparation, irregular surface on the inner wall of cortex is noted. **C**, The cavity wall was detected and explored by a periodontal curette, revealing a hollow space surrounding the site for dental implant. **D**, After thorough cleaning of the cavity by surgical curette and irrigation with normal saline, the cavity is filled with synthetic alloplast grafting material. **E**, The cavity should be completely filled with bone grafts and then distributed evenly, leaving only a space for implant placement. **F**, In this case, a short, 4.5 × 6-mm locking-taper implant is placed into the constructed hole and tapped 2 mm below the crest. **G**, The flap is closed for primary healing. **H**, Postoperative radiograph showed graft filling and implant in site. The implant shoulder is located 2 mm below the crest. (Note: The dental amalgam restoration on the second molar and composite resin restoration on the second premolar adjacent to the edentulous region were performed by the dentist in a local dental clinic. The quality was compromised. But because the patient refused to change the restorations due to no symptoms, we could only suggest the patient to keep follow-up at our clinic and have the restoration redone if any secondary caries or symptoms were found.)

BC, such as osteonecrosis of the jaw (ONJ), neuralgia-induced cavitation osteonecrosis (NICO), condensing osteitis, focal osteoporotic marrow defect (FOMD), and traumatic bone cysts. There are still controversies on the etiology, diagnostic definition, and treatment of some of these disease entities. But an entity of disease which almost always causes pain mimicking the symptom of trigeminal neuralgia is mostly categorized to NICO,^{9,10} whereas ONJ should have a clinical, radiographic, or pathological clue of bone necrosis.^{11,12}

If an implant has an unexpected displacement into a space which is not a true anatomical one, BC might be the cause. Although cases of BC were rarely reported in the literature and often regarded as clinically insignificant conditions, we have found a considerable number of cases during implant surgeries, which drew our attention. In this study, we present a consecutive 34 cases of BC which

were found after surgical flap elevation and osteotomy for preparation of implant placement. Microscopic examination of the scarce tissue retrieved in the BC revealed FOMD as the diagnosis. Alloplast bone substitute (β -tricalcium phosphate [β -TCP]) grafting with immediate or staged dental implant placement was performed to reconstruct the jawbone defects and restore the missing teeth. This is the first study documenting an implant and graft treatment of BC. We emphasize the importance of careful examination of the surrounding tissue where the implants will be placed, and a concise literature review of FOMD is also presented.

MATERIALS AND METHODS

Between August 2012 and August 2014, 209 patients with edentulous ridge of maxillae or mandible were treated with at least one implant in the Dental Implant Unit of Oral Surgery and Medicine Department, University

of Cartagena, Colombia. Medical charts were reviewed, and complete clinical and radiographic records of 34 consecutive cases with BC were retrieved for this study. All these patients with BC have been followed up for at least 3 years postoperatively. They were inquired for a complete medical and drug history about neoplasm, bone disease, metabolic disease, hematologic disease, and hormone therapy. Previous dental treatment history and the reason for exodontia in the edentulous region were also collected. Approval for study conduction was obtained from the Ethical Board at the Dental Faculty Research Committee at the University of Cartagena (Ethics Review Committee, ERC approval No: Record No. 3, October 2014).

All 34 patients came to the Dental Implant Unit, requesting for dental restorations on their edentulous region. None of them presented with symptoms of pain, swollen, inflammation, infection, paresthesia, or dysesthesia on

Table 1. Patient Demographic (Age, Gender, and History of Diseases and Drugs) and Clinical Data (Numbers of BC and Implant-Related Information)

Patient Characteristics (n = 34)	
Age, mean \pm SD, y	55.44 \pm 11.87
Age range, y	25–83
Males/Females	11/23
Systemic disease (yes/no)	20/14
Skeletal problems (yes/no)	5/29
Hematological disorders (yes/no)	0/34
Taking drugs (yes/no)	24/10
Steroid therapy (yes/no)	2/32
Hormone therapy (yes/no)	0/34
Habit of cigarette smoking (yes/no)	2/32
Habit of alcohol consumption (yes/no)	9/25
Jawbone cavitation (n = 41)	
Position on maxillae/mandible	2/39
Dental implant characteristics (n = 52)	
Stage of dental implantation (1-time surgery/staged surgery)	38/14
Implants' position (anterior teeth/premolars/molars)	0/12/40
Implant length (5.0/6.0/8.0/11.0)	6/16/27/3

maxillofacial regions. There were totally 54 edentulous tooth positions needing to be restored. The teeth have been extracted for 21 to 420 days (mean: 141 ± 95). All patients received thorough evaluation based on clinical dental conditions, and dental radiographs were taken for implant planning. Clinical examination included all routine preoperative implant surgery evaluations, eg, bone volume, jaw relations, intermaxillary distance, occlusal relation, and conditions of the opposing dentition. Anatomical conditions and possible pathological lesions in the jaws were evaluated with panoramic and intraoral periapical radiographs. Periapical radiographs were performed using radiovisiography with parallelism technique (Dr. Suni Plus; Suni Medical Imaging, San Jose del Oro, CA). There were unremarkable findings on clinical examination in all patients. None of the radiographic examinations revealed obvious abnormal rarefaction shadows on their edentulous region (Fig. 1, A).

After fully explaining to the patients, they completed the written informed consent, and patients who had habits of cigarette smoking were requested to cease smoking at least 1 week before and for 3 months after surgeries.

Surgical and Restorative Treatment

Antibiotics premedication was prescribed 1 day before the surgery, and all

the patients received 500 mg amoxicillin (or 300 mg clindamycin instead if the patient was reported to have allergic reaction to penicillin) every 8 hours for a total of 3 doses before surgeries. Immediately before surgical procedures, each patient was instructed to rinse the oral cavity with 0.2% chlorhexidine (Farpag Laboratories, Bogotá DC, Colombia) mouthwash for 1 minute and then received local anesthesia using lidocaine with adrenaline 1:100,000 (Xylocaine; Dentsply Pharmaceutical York, Pennsylvania). Surgeries began with a crestal incision made on the edentulous ridge, and full-thickness envelope or triangular flaps were reflected to expose the underlying bone. All of the cortical crestal surface of alveolar ridges where intact, thus osteotomies were performed until the planned diameter and depth had been reached (Fig. 1, B). There was no abnormal fluid discharge, but obvious loosening bone density was felt when doing osteotomies in these cases. The walls and floor were carefully explored with a Lucas curette (Fig. 1, C). A hollow bone cavitation was found in the marrow space in all of our cases, and the extension of defects was determined using periodontal gauge probes. There was nearly empty tissue but a little amount of blood in the bone cavity. Besides, sparse thin membranous-like tissue was found by curettage around the wall. Some of these obtainable tissues

were sent for histological examination to rule out any pathological conditions.

Defects extending beyond the dental socket, with less than 5 to 6 mm width and 10 mm depth, were treated by simultaneous synthetic alloplast grafting (β -TCP; SynthoGraft, Bicon, MA) and locking-taper implant placement (Fig. 1, D–F). If the defect was more than the size mentioned above, only grafting was performed, and a 6-month clinical and radiographic follow-up was done for bone filling, and further dental implantation was arranged. A second stage of surgery was performed 4 to 6 months after implant placement with also a mid-crestal incision to uncover the submerged implants. A healing abutment was connected, and the wound was allowed to heal for at least 2 weeks. All the patients were then referred to one of the two prosthodontists for fixed implant restoration with either single crown or splinted bridge. There were totally 38 implants placed with simultaneous β -TCP grafting in 27 patients (32 BCs), while the other 7 patients (9 BCs) received β -TCP grafting for the first surgery and then staged dental implantation as the second surgery due to extensiveness of the BC. One experienced oral surgeon conducted all surgical treatments.

After each stage of surgery, amoxicillin (500 mg) was prescribed every 8 hours for 7 days, and if the patient was allergic to penicillin or its derivatives, clindamycin (300 mg) every 8 hours was prescribed instead. All the patients were instructed to clean their teeth using finger-held gauze with essential oils (Listerine, Johnson & Johnson de Colombia, Bogota DC, Colombia).

Follow-Ups

All the 34 patients have been recalled for routine clinical examinations after grafting and implant surgeries, which were at 1, 2, and 4 weeks postoperatively. Sutures were removed at the 2-week follow-up. Then, they were recalled for the first postoperative radiographic examination 6 months after the first-stage procedure. Other radiographic follow-up appointments were arranged 6 months after the second-stage procedure. All the patients have been followed up at least 6

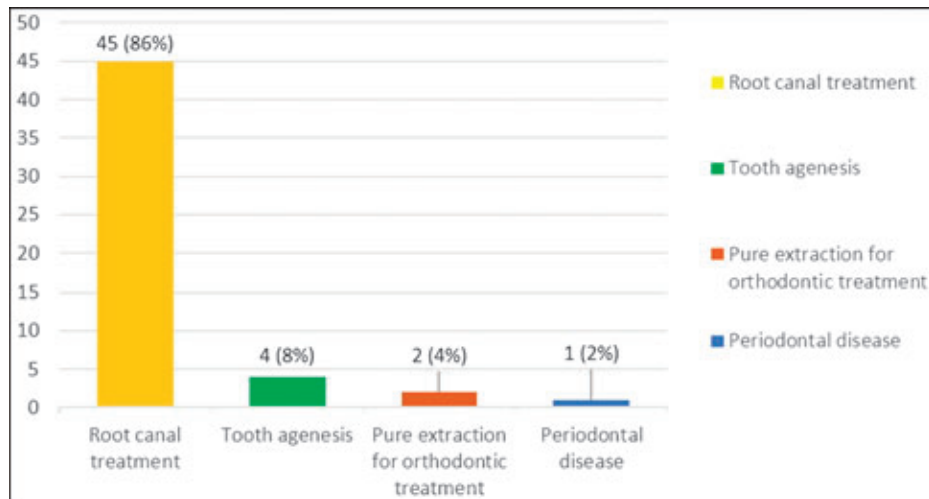


Fig. 2. The bar graph illustrating patients' dental treatment history at the region of BC. Thirty patients with 45 missing teeth regions with BC underneath had RCTs history. Two patients (3 missing teeth regions with BC underneath) had tooth extraction due to chronic periodontitis and 1 patient (4 regions) due to tooth agenesis. One patient had 2 teeth extracted for orthodontic treatment need.

months after first-stage operation, and the average follow-up duration was 24 months (range: 10–36 months).

Evaluation Method

Implant-related parameters and any variables possibly related to jaw BC were retrieved. Descriptive statistics

(mean, ranges, and SD) were reported for the patients' systemic diseases, drug intakes, and previous dental histories (case of exodontia). Statistical analyses were performed using computer software (SPSS 17.0; SPSS Inc., Chicago, IL). Surgical complications were recorded according to the following:

Complications included symptoms of pain or paresthesia at surgical region, continuous objective inflammatory and infection signs, and persistent radiolucency or loss of graft on radiographic images. Implant failure is defined as (1) removal of implant due to any complication or (2) clinically

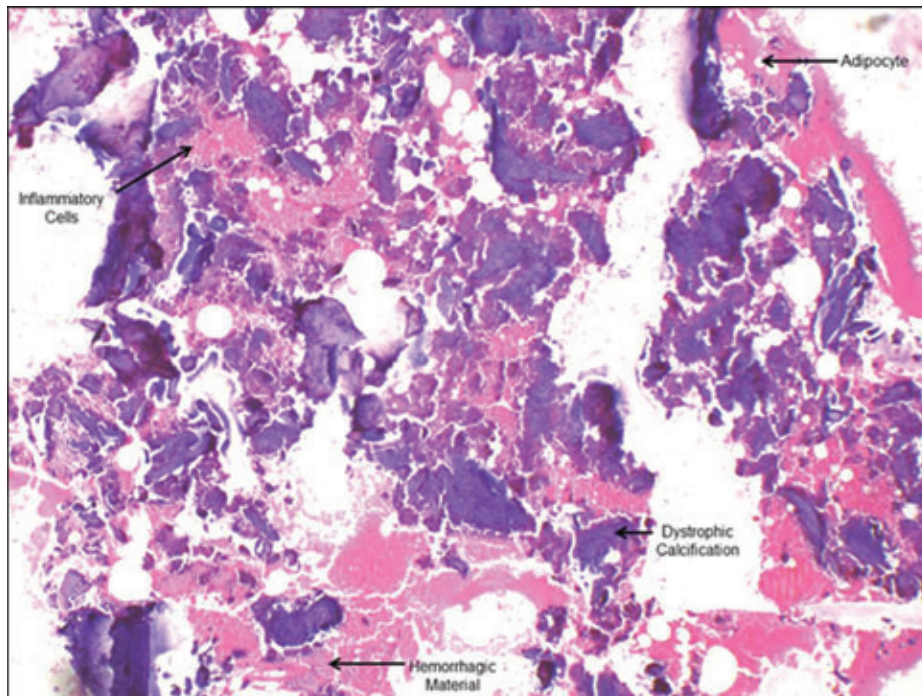


Fig. 3. Histological examination reveals hematopoietic and fatty marrow with a large area of dystrophic calcification and minimal cellular content (arrows). (hematoxylin and eosin stain, $\times 40$).

Table 2. Life-Table Analysis and Cumulative Survival Curve of Implants on BCs

Period, mo	Implants	Failed	Lost to Follow-Up	CSR%
6 mo	52	0	0	100
6–12 mo	52	0	0	100
12–24 mo	48	0	0	100
24–36 mo	17	1	0	98.1

CSR indicates cumulative survival curve.

mobile implant with the patient's awareness of loss of chewing function. The rate of complication or failure was expressed as a percentage among the total number of implants placed. Survival analysis and a life-table method were used to estimate the prognosis for the 6-month to 3-year cumulative survival rate of implants.

RESULTS

Distribution of cases according to age, sex, medical and dental history, as well as BC and implant types is summarized in Table 1. The patients included 11 men and 23 women (aged 25–83 years), with a mean age of 55.44 ± 11.87 years. Regarding medical history, 20 patients had systemic disease but not contraindicated local surgical treatments. There are 7 patients (7/34) with hypertension and 4 patients (4/34) with diabetes mellitus, and all of them have been taking anti-hypertensive and antidiabetic agents. There is only one patient with osteopenia and another one with osteoporosis, and both of them were only taking calcium tablets. None of them had history of malignant neoplasms, hematological disorders, or autoimmune diseases. In regard to the drugs taken by the patients, most of them were prescriptions in correspondence to their systemic disease. Among them, 2 patients were under corticosteroid therapy for asthma, 2 patients were under insulin replacement therapy, and 1 patient was under thyroid replacement therapy. Besides, 3 patients took calcium tablets for dietary supplement, and over-the-counter nonsteroid anti-inflammatory drugs were taken occasionally. History of taking any bisphosphonate agents was denied.

To analyze the possible related factor of BC, the reasons for extraction

of teeth or dental treatment history in the region were also retrieved. Most of the patients with BC (30 of 34 patients with 45 missing teeth regions with BC underneath) had root canal treatments (RCTs) history, whereas the others had their teeth extracted due to chronic periodontitis (2 patients with 3 missing teeth regions) and tooth agenesis (1 patient with 4 missing teeth regions) and for orthodontic treatment needs (1 patient with 2 missing teeth regions) (Fig. 2).

Of the 41 BCs found in 34 patients, nearly all (39/41) were found in the mandible and only 2 were in the maxillae. Seven patients were found to have BC in the mandible bilaterally. Twenty-seven patients (with 32 BCs) received β -TCP grafting and 38 dental implantation in one-time surgery, whereas the other 7 patients (with 9 BCs) received β -TCP grafting only and staged implant surgeries for 16 tooth positions were planned. After a 6-month follow-up examination, 6 patients showed bone fill in the BC and received dental implantation successfully (14 implants in 7 BCs). However, 1 patient had symptoms of throbbing pain 1 month postoperatively, and graft loss was noticed in his bilateral mandibular BC during follow-up period. Implant surgery was not performed. This patient had a medical history of osteoporosis, and it was found by the proximity of the BC to inferior alveolar nerves, which was considered to be the cause of pain.

Histological Findings

Eight patients had available tissue from curettage for histological examination. All these multiple tissue slides showed adipose tissue with large dystrophic calcifications surrounded by hemorrhagic material and mixed inflammatory cells. No evidence of epithelial lining or malignant cells was noted (Fig. 3). The histopathological

features, though nonspecific, resemble to that of the FOMD.

Outcomes of Implant on BC

Of the 52 implants, 22 were of 5 and 6 mm length and 30 were of 8 and 11 mm. The implant diameter ranged from 4 to 6 mm. The implant positions were distributed in premolar (12/52) and molar (40/52) regions (Table 1). By the end of 3-year follow-up period, 1 implant failed and resulted in an overall failure rate of 1.9%. This failed implant was originally placed in the lower molar region with the graft as one-time surgery. A single crown has been restored on it. But loss of osseointegration at 25 months postoperatively was shown, and it was removed eventually.

All the other remaining implants were free of complications and functioned well, resulting in a 3-year cumulative survival rate of 98.1% (Table 2).

DISCUSSION

In this retrospective cohort study, we introduced an approach to treat BCs with synthetic alloplast grafting and dental implantation. All the patients had very similar clinical situations: They came without remarkable symptoms and signs on the edentulous region to be treated by dental implantation, and hollow marrow space or bone cavitations were found not until osteotomies were made. We suspect that the BCs in these cases might all be FOMDs, for 8 of the cases with available specimen were histologically compatible with the diagnosis.

FOMDs, with some synonyms such as focal osteoporotic bone marrow defects (FOBMDs) and osteoporotic bone marrow defects (OBMDs), are considered to be a rare condition of the jaws because they are asymptomatic and only some of the cases could be found on plain radiographic examination. The FOMD usually presents with a poorly demarcated radiolucency with variable density. Only when it is observed under radiography with other disease possibilities being considered, a biopsy will be performed and a pathological diagnosis be established.¹³ Also because of that, the incidence of this jaw lesion is hard to determine.

However, a recent research analyzing 9723 cases of jawbone radiolucency showed that FOMD accounted less than 1% of the lesions.¹⁴

The first available documented largest case series of FOMDs was in 1974,¹⁵ which reported the detailed clinical, radiographic, and histological characteristics of a total of their own 197 cases. In addition to Barker's article, there were another 3 case series,¹⁶⁻¹⁸ which showed remarkable consistency in their cases with regard to sex, age, symptoms, location etc. They constructed a typical epidemiological, clinical, radiographic, and histological description of FOMDs. After then, several individual case reports have demonstrated various FOMDs with different manifestations.^{3,13,19-22} From all the above published literature, it can be summarized that FOMDs predominantly affected middle-aged female patients, and most cases occurred in the mandibular molar area. FOMDs can be located either in areas adjacent to teeth or of previous extractions.²³ Our cases, however, were all involved edentulous regions of jaws because the patients originally came for dental restorations and the BCs were found fortuitously.

Recently, there were 2 case report articles of FOMDs being related to implant problems.^{3,21} One of them was a report of 3 cases involving displacement of implants into the FOMDs immediately and 2 days after the implants were placed.³ We would like to address the importance that such cases might not be uncommon, and some other reported cases with dental implants displacement into mandible marrow space might also be related to FOMDs,^{2,4} and these aspects highlight the importance of an early detection through x-rays or even a higher resolution image examination such as computerized tomography. This can yield a more accurate treatment planning, and thus, a higher success rate can be guaranteed for the patient.

The etiological factors of FOMDs are still unknown. Makek et al¹⁶ reviewed 276 reported FOMD cases, and they found that 151 of them had concomitant pathological or odontogenic conditions. Shankland et al²⁴

however, summarized 3 theories proposed in the previous literature: (1) marrow hyperplasia after an increased demand for blood cells resulting in bone resorption, (2) residual hematopoietic marrow persisting into adulthood, and (3) defective regeneration of bony trabeculae in an area of previous trauma, local inflammation, or surgery. They also provided a fourth theory that FOMD is an early form of ischemic osteoporosis secondary to a malfunction of blood flow within the marrow, based on half of their 100 FOMD cases showing evidence of degeneration, ischemia, or necrosis on microscopic examination. Because most of our cases had history of endodontic treatment on teeth being extracted, we are more prone to the theory of an abnormal post-healing process after extraction of the tooth predisposed to some inflammatory condition to be the most possible cause of the lesions. We would also like to postulate that FOMDs might be a form of osteoporosis that solitarily or concomitantly occur with systemic osteoporosis because the peak population of FOMDs is quite the same with systemic osteoporosis which is very common among postmenopausal women.

Current biomaterials used for endodontic irrigation during RCT, such as sodium hypochlorite (NaOCl), are reported to have deleterious effects on the bone structure. Some authors have reported localized interdental bone necrosis after RCT.²⁵ Specifically, Kerbl²⁶ described on dogs the degradation of the organic matrix, and grossly, NaOCl caused significant changes in cancellous structure, leaving it less dense and also large structural craters of apparent demineralization. Because FOMD's etiology is not fully understood and having in mind that in this study, most of the patients had previous RCT on those sites, it is possible that the material extrusion to the bone can explain the defect's presence. Moreover, further studies are needed to confirm these hypotheses.

Nevertheless, the upmost strategy to deal with suspected BCs having an ill-defined radiolucent shadow is to consider other cystic, neoplastic,

hematological, and also metastatic diseases as first differential diagnoses. Once aggressive or devastating lesions are carefully ruled out and the diagnosis of FOMD is made, in contrary to "watchful waiting," this article has provided a practical treatment protocol for them. Within a 3-year follow-up, a fair clinical outcome of grafting and dental implantation in these patients is shown. Although there was 1 case with a medical history of osteoporosis shown to have graft loss, no other complications were found. We thought a patient with a medical history of osteoporosis is another critical issue to draw attentions, but we are not discussing it in this study.

CONCLUSION

BC in the edentulous region is no more considered to be uncommon; it can result in implant displacement if overlooked. In this study, we consider that the BCs were corresponding to an entity of focal osteoporosis called FOMDs. They could be treated by alloplast grafting and dental implantation, which is shown to have satisfactory clinical outcomes. Nonetheless, a long-term follow-up result of these cases and an in-depth exploration of the pathogenesis and correlation with local and systemic factors are still mandatory in future research.

DISCLOSURE

The authors claim to have no financial interest, either directly or indirectly, in the products or information listed in the article.

APPROVAL

Approval for study conduction was obtained from the Ethical Board at the Dental Faculty Research Committee at the University of Cartagena. (Ethics Review Committee, ERC approval No: Record No. 3, October 2014).

ACKNOWLEDGMENTS

The authors thank the Dental Implant Unit's clinical staff for their assistance in the surgical procedures

and patients' follow-up, and a third-year dental student, Salin Insignares, for his assistance in the data collection.

REFERENCES

- González-García A, González-García J, Diniz-Freitas M, et al. Accidental displacement and migration of endosseous implants into adjacent craniofacial structures: A review and update. *Med Oral Patol Oral Cir Bucal*. 2012;17:e769–e774.
- Doh RM, Pang NS, Kim KD, et al. Implant displacement into the mandible: An unusual complication during implant surgery. *Implant Dent*. 2011;20:345–348.
- Lee SC, Jeong CH, Im HY, et al. Displacement of dental implants into the focal osteoporotic bone marrow defect: A report of three cases. *J Korean Assoc Oral Maxillofac Surg*. 2013;39:94–99.
- Bayram B, Alaaddinoglu E. Implant-box mandible: Dislocation of an implant into the mandible. *J Oral Maxillofac Surg*. 2011;69:498–501.
- Theisen FC, Shultz RE, Elledge DA. Displacement of a root form implant into the mandibular canal. *Oral Surg Oral Med Oral Pathol*. 1990;70:24–28.
- Lamas Pelayo J, Peñarrocha Diago M, Martí Bowen E, et al. Intraoperative complications during oral implantology. *Med Oral Patol Oral Cir Bucal*. 2008;13:E239–E243.
- Noel HR. A lecture on caries and necrosis of bone. *Am J Dent Sci* 1. 1868;1:425–482.
- Black GV. *A Work on Special Dental Pathology*. Chicago, IL: Medico-Dental Co; 1915:388–391.
- Bouquot JE, Roberts AM, Person P, et al. Neuralgia-inducing cavitation osteonecrosis (NICO). Osteomyelitis in 224 jawbone samples from patients with facial neuralgia. *Oral Surg Oral Med Oral Pathol*. 1992;73:307–319.
- Ratner EJ, Langer B, Evins ML. Alveolar cavitation osteopathosis. Manifestations of an infectious process and its implication in the causation of chronic pain. *J Periodontol*. 1986;57:593–603.
- Ruggiero SL, Dodson TB, Fantasia J, et al. American Association of Oral and Maxillofacial Surgeons position paper on medication-related osteonecrosis of the jaw—2014 update. *J Oral Maxillofac Surg*. 2014;72:1938–1956.
- Magremanne M, Picheca S, Reyckler H. Etiologic diagnosis of jaw osteonecrosis, other than bisphosphonate and radiotherapy related osteonecrosis. *Rev Stomatol Chir Maxillofac Chir Orale*. 2014;115:45–50.
- Almeida LY, Kato RB, Ribeiro MC, et al. Focal osteoporotic bone marrow defect mimicking a mandibular cystic lesion. *J Craniofac Surg*. 2014;25:e324–326.
- Koivisto T, Bowles WR, Rohrer M. Frequency and distribution of radiolucent jaw lesions: A retrospective analysis of 9,723 cases. *J Endod*. 2012;38:729–732.
- Barker BF, Jensen JL, Howell FV. Focal osteoporotic bone marrow defects of the jaws. An analysis of 197 new cases. *Oral Surg Oral Med Oral Pathol*. 1974;38:404–413.
- Makek M, Lello GE. Focal osteoporotic bone marrow defects of the jaws. *J Oral Maxillofac Surg*. 1986;44:268–273.
- Crawford BE, Weathers DR. Osteoporotic marrow defects of the jaws. *J Oral Surg*. 1970;28:600–603.
- Standish SM, Shafer WG. Focal osteoporotic bone marrow defects of the jaws. *J Oral Surg Anesth Hosp Dent Serv*. 1962;20:123–128.
- Chiang CP, Yang H, Chen HM. Focal osteoporotic marrow defect of the maxilla. *J Formos Med Assoc*. 2015;114:192–194.
- Bravo-Calderón DM, Oliveira DT, Martins Dos Santos WH. Bilateral osteoporotic bone marrow defects of the mandible: A case report. *Head Face Med*. 2012;8:1–3.
- Sencimen M, Delilbasi C, Gulses A, et al. Focal osteoporotic hematopoietic bone marrow defect formation around a dental implant: A case report. *Int J Oral Maxillofac Implants*. 2011;26:e1–e4.
- Gordy FM, Crews KM, Carroll MK. Focal osteoporotic bone marrow defect in the anterior maxilla. *Oral Surg Oral Med Oral Pathol*. 1993;76:537–542.
- Schneider LC, Mesa ML, Fraenkel D. Osteoporotic bone marrow defect: Radiographic features and pathogenic factors. *Oral Surg Oral Med Oral Pathol*. 1988;65:127–129.
- Shankland WE, Bouquot JE. Focal osteoporotic marrow defect: Report of 100 new cases with ultrasonography scans. *Cranio*. 2004;22:314–319.
- Reddy KK, Shankar BS, Reddy KA, et al. Localized interdental bone necrosis: A case report. *J Int Oral Health*. 2014;6:73–75.
- Kerbl FM, DeVilliers P, Litaker M, et al. Physical effects of sodium hypochlorite on bone: An ex vivo study. *J Endod*. 2012;38:357–359.