



Technical procedure

Metal free, full arch, fixed prosthesis for edentulous mandible rehabilitation on four implants



Alfredo Passaretti^a, Giulia Petroni^a, Giovanna Miracolo^b, Valeria Savoia^b,
Angelo Perpetuini^b, Andrea Cicconetti^{a,*}

^a Department of Oral and Maxillofacial Sciences, Sapienza University of Rome, Italy

^b Private Practice, Rome, Italy

ARTICLE INFO

Article history:

Received 30 November 2015

Received in revised form 4 September 2017

Accepted 20 October 2017

Available online 7 December 2017

Keywords:

Trinia

Fiber reinforced composite material

Metal-free

Short implant

ABSTRACT

Purpose: The goal of this work is to describe an implant-prosthetic protocol for rehabilitation of edentulous mandible, by using a fixed prosthesis made of fiber-reinforced composite material (FRC). The protocol contemplates a minimal invasive surgery and ensures predictable and safe results, with good aesthetic and performance combined to cost savings.

Methods: FRC material is used to build the substructure of a prosthetic framework supported by four short implants (5 mm long and 4 mm wide). The prosthesis substructure is made of Trinia immersed in a matrix of epoxy resin (FRC). It is supplied in milling blocks (pre-cured) for the CAD/CAM (computer-aided design/computer-aided manufacturing) technique.

Implants are placed in lower edentulous jaw in position of first molar and canine, each side. Four month after, a resin bar is build based on a stone model, denture teeth are placed and the occlusion is checked. The resin bar and the stone model with milled abutments are scanned and a FRC bar is achieved with the CAD/CAM technique. The teeth are mounted to the substructure trough denture resin. Temporary cementation of framework is achieved on the abutments connected to the implants.

Conclusion: A protocol for a fixed mandibular implant-prosthetic rehabilitation is described. The protocol contemplates a minimal invasive surgery and ensures predictable and safe results, with good aesthetic and performance combined to cost savings. In addition, this technique allows performing basic surgery also in presence of atrophy.

© 2017 Japan Prosthodontic Society. Published by Elsevier Ltd. All rights reserved.

1. Introduction

Replacing dental tissues is one of the primary goal of dentistry. Continuous research for dental materials able to reproduce teeth is carried on. Although metal ceramic restoration is still the gold standard in prosthetic dentistry [1,2], in the last few years the interest was focused on composite materials [3–6]. Many studies have been conducted [7–12] to evaluate the performance of fixed partial dentures made of composite material, which offer several advantages over traditional metal-ceramic systems, including: improved aesthetics, a biomechanical behavior more akin to natural dentition (biomorphism) and the possibility of repairing or modifying denture chairside [11,13]. The main alternatives to the metals

are pressed ceramic, zirconia ceramics and fiber-reinforced polymer (FRP) materials. Given the limited applications of pressed ceramic [14,15] and the frequent “chipping” of porcelain layered on zirconia ceramics, research interest has turned toward fiber-reinforced polymer (FRP) [16–19].

Fiber-reinforced composite material (FRC) materials have been shown to achieve better functional-esthetical result and a good bio-tolerability [20–24]. In this study, we describe an implant-prosthetic protocol for rehabilitation of edentulous mandible, by using a fixed prosthesis made of FRC. The protocol contemplates a minimal invasive surgery and ensures predictable and safe results, with good aesthetic and performance combined to cost savings.

2. Materials and methods

2.1. Indications to the technique

This procedure is indicated in all cases of edentulous mandible needing a fixed rehabilitation [25–27]. Particularly, the technique

* Corresponding author at: Department of Oral and Maxillofacial Sciences, School of Dentistry, Sapienza University of Rome, Via Caserta 6, 00161 Rome, Italy.
E-mail address: andrea.cicconetti@uniroma1.it (A. Cicconetti).

is indicated to patients with a mandibular complete denture who complain for discomfort or poor esthetic results.

2.2. Patient selection

Patients with mobile prosthesis in the lower jaw were recruited, based on clinical and radiographic examinations.

2.3. Surgical procedure

Patients receive four short implants (Bicon LLC, Boston, MA, USA), 4 mm in diameter and 5 mm in height to support the fixed prosthesis. The implant is characterized by a plateau design, a crestal module with pure locking taper connection, sloping shoulder, abutment hemispheric profile and calcium phosphate based treatment. The implants and abutments of the system are made from Ti-6Al-4V alloy.

Implants are inserted in lower edentulous jaw in position of first molar and canine, each side, through small surgical access. Four months after the first surgical stage, the implants are uncovered and healing abutments are placed.

2.4. Prosthetic procedure

The prosthesis substructure is made of Trinia (Bicon LLC) made up of interlaced multidirectional, multilayered fiberglass, immersed in a matrix of epoxy resin (FRC). It is supplied in milling blocks (pre-cured) for the CAD/CAM (computer-aided design/computer-aided manufacturing) technique.

After 15 days of healing, the abutments are removed and related transfers with their copings are connected to the fixtures (Fig. 1). An implant-level transfer impression is recorded in silicone material. The bite is recorded with articulation wax.

The stone model reproducing the position of the implants in the oral cavity is mounted in an articulator with the antagonist. Appropriate abutments are selected and milled parallel to one another with a 2–4° axis (Fig. 2). The model with the milled abutments is used to fabricate a light cured resin bar, and then used to set up denture teeth for an intra-oral confirmation.

Once the denture set-up has been clinically approved, a facial occlusal silicone mask is formed over the denture wax set-up. Denture teeth are removed from the resin bar and glued to the silicone mask with a cyanoacrylate glue. The stone model with the milled abutments and the resin bar are sprayed separately and digitally scanned (DS Scan, EGS).

The fiber-resin bar is digitally designed (EXOCAD) on the computer, with a minimum thickness of 7.0 mm throughout, an abutment clearance of 30 microns for cement and a maximum

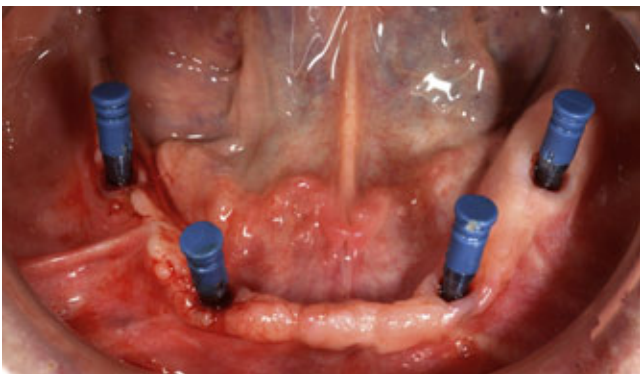


Fig. 1. Implants with transfers and copings in position ready for impression. The implants are placed at the position of canine and first molar, each side.

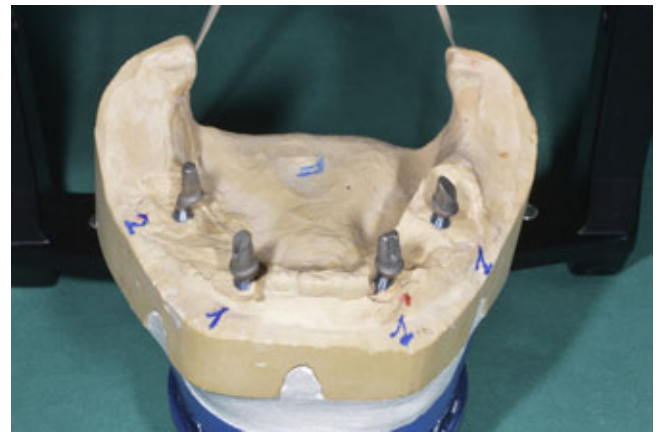


Fig. 2. Stone model with milled abutments. The parallel milling is necessary to achieve a passive fitting of prosthesis.

cantilever extension of 21.0 mm. The project is realized using a milling machine operating on five axes (Roland DWX-50). The machine uses diamond-hardened drills and works at 1 and 2 mm to 16,000 rpm for the roughing stage and up to 25,000 rpm in the finishing stage (Fig. 3).

After the milling, the bar is manually reduced and checked on the stone model with the abutments. Additionally, the sequence of insertion of the milled abutments is defined and the fitting is verified with the silicone mask. A denture resin is poured into the silicone mask to secure teeth to the bar. Final polymerization is achieved under hot water, with an air pressure of three bars. After polymerization, the prosthesis is removed from its silicone mask, and then finished and polished in a conventional manner.

The prosthesis itself is used to orient and place the abutments in the well of the implants following the pre-ordered sequence. The fitting of the framework is checked and the Morse taper connection is activated. Temporary cementation of framework is achieved (TempBond, Kerr). The occlusion is evaluated and adjusted (Figs. 4 and 5).

3. Difference from conventional methods

The first difference from conventional methods is that this procedure limits the indications for bone graft or regeneration, thus using the residual native bone. This is important because horizontal and vertical bone augmentation procedures are



Fig. 3. Fiber-composit disk during milling process. After the digital design, the project is realized through a milling machine.

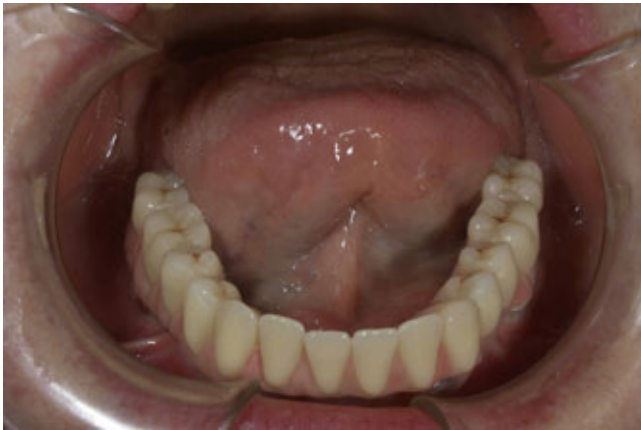

Fig. 4. Intra-oral view, framework is cemented to abutments.

subjected to variable efficacy [28], cause more stress to patients and have longer rehabilitation period.

In addition, the use of short implants in native bone limits the indication to tilted implants. As observed by some authors, stress distribution around implant angulated more than 35° can lead to fail [29–31].

The technique presented does not use the immediate load protocol because it is demonstrated that, to ensure a bone formation, it is necessary neo-angiogenesis [32] and cement line formation [33]. In order to immediately load an implant, a primary stability is required, with a bone compression that often may cause reabsorption and replacement with non-functional, avascular bone [34]. In addition, patients eligible for this protocol are often already denture wearers.

The second difference is related to the framework material. According to several authors, FRC allows better distribution of occlusal loads [35], while performance are comparable to other materials [7,24]. The FRC may absorb energy from the masticatory cycle, because of the lower flexural modulus of the material compared to metal alloys [35]. This effect becomes an advantage as it contributes to the maintenance of the peri-implant bone [35].

Another difference concerns bio-tolerability. The reference material (metal alloy) is used despite a lack of robust clinical tolerance studies [36]. Corrosion represents a concrete risk, as cobalt and nickel are released into the oral cavity [37–40], and long-term effects have not yet been fully discovered [1,37,41,42]. The use of a metal-free prosthesis may solve the problems related

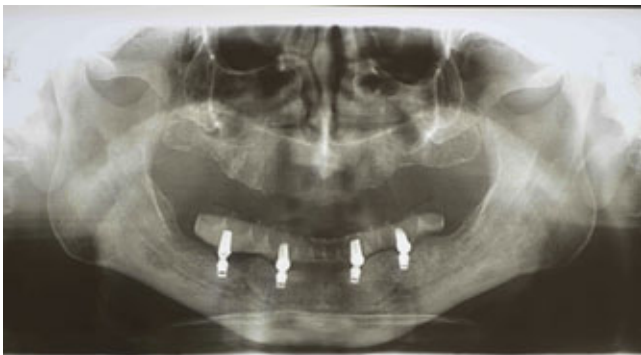

Fig. 5. Radiographical evaluation, note the subcrestal position of implants, the metal-free substructure with denture teeth in position. The opposite dentition in this patient was a complete removable denture.

to metal structures such as corrosion, toxicity, complexity of manufacture, economic cost and aesthetic limitations [4,37–40].

4. Effect or performance

This technique allows performing basic surgery also in presence of atrophy. The characteristics of the prosthesis allow the use of only four implants. The main advantages for the patient consist in reduced rehabilitation time, minor trauma, better bio-tolerability of prosthesis, good esthetic and minor treatment cost.

5. Conclusion

A protocol for a fixed mandibular implant-prosthetic rehabilitation is described. The protocol could also be useful to atrophic mandibles, ensuring secure, accurate, and safe implant placement with minimal invasiveness and providing a fixed FRC-denture-teeth prosthesis for a durable and cost effective rehabilitation. Moreover, the mechanical characteristics of Trinia, comparable to traditional materials, could make it a viable alternative to metal in the production of prosthetic structures.

Ethics

The work has been approved by the ethics committees and subjects gave informed consent to the work (protocol number of ethic approval is prot. 628/13 “rif.2791/13-06-2013).

References

- [1] Kelly JR, Rose TC. Nonprecious alloys for use in fixed prosthodontics: a literature review. *J Prosthet Dent* 1983;49:363–70.
- [2] Silva , Bonfante EA, Zavanelli RA, Thompson VP, Ferencz JL, Coelho PG. Reliability of metaloceramic and zirconia-based ceramic crowns. *J Dent Res* 2010;89:1051–6.
- [3] Belvedere PC. A metal-free single sitting fibre-reinforced composite bridge for tooth replacement using the EOS-system. *Swiss Dent* 1990;11:7–18.
- [4] Vallittu PK, Sevelius C. Resin-bonded, glass fiber-reinforced composite fixed partial dentures: a clinical study. *J Prosthet Dent* 2000;84:413–8.
- [5] Freilich MA, Meiers JC, Duncan JP, Eckrote KA, Goldberg AJ. Clinical evaluation of fiber-reinforced fixed bridges. *J Am Dent Assoc* 2002;133:1524–34.
- [6] Ellakwa A, Thomas GD, Shortall AC, Marquis PM, Burke FJ. Fracture resistance of fiber-reinforced composite crown restorations. *Am J Dent* 2003;16:375–80.
- [7] Behr M, Rosentritt M, Lang R, Handel G. Flexural properties of fiber reinforced composite using a vacuum/pressure or a manual adaptation manufacturing process. *J Dent* 2000;28:509–14.
- [8] Bae JM, Kim KN, Hattori M, Hasegawa K, Yoshinari M, Kawada E, et al. The flexural properties of fiber-reinforced composite with light-polymerized polymer matrix. *Int J Prosthodont* 2001;14:33–9.
- [9] Keulemans F, Palav P, Aboushelib MM, van Dalen A, Kleverlaan CJ, Feilzer AJ. Fracture strength and fatigue resistance of dental resin-based composites. *Dent Mater* 2009;25:1433–41.
- [10] Van Heumen CC, Kreulen CM, Creugers NH. Clinical studies of fiber-reinforced resin-bonded fixed partial dentures: a systematic review. *Eur J Oral Sci* 2009;117:1–6.
- [11] Başaran EG, Ayna E, Vallittu PK, Lassila LV. Load bearing capacity of fiber-reinforced and unreinforced composite resin CAD/CAM-fabricated fixed dental prostheses. *J Prosthet Dent* 2013;109:88–94.
- [12] Ohlmann B, Bermejo JL, Rammelsberg P, Schmitter M, Zenthöfer A, Stober T. Comparison of incidence of complications and aesthetic performance for posterior metal-free polymer crowns and metal-ceramic crowns: results from a randomized clinical trial. *J Dent* 2014;42:671–6.
- [13] Garoushi S, Vallittu PK. Chairside fabricated fiber-reinforced composite fixed partial denture. *Libyan J Med* 2007;2:40–2.
- [14] El-Mowafy O, Brochu JF. Longevity and clinical performance of IPS-Empress ceramic restorations, a literature review. *J Can Dent Assoc* 2002;68:233–7.
- [15] Pjetursson BE, Sailer I, Zwahlen M, Hammerle CH. A systematic review of the survival and complication rates of all-ceramic and metal-ceramic reconstructions after an observation period of at least 3 years. Part I: single crowns. *Clin Oral Implants Res* 2007;18:73–85.
- [16] Larsson C, Vult von Steyern P, Sunzel B, Nilner K. All-ceramic two- to five-unit implant-supported reconstructions. A randomized, prospective clinical trial. *Swed Dent J* 2006;30:45–53.
- [17] Sailer I, Gottner J, Kanel S, Hammerle CH. Randomized controlled clinical trial of zirconia-ceramic and metal-ceramic posterior fixed dental prostheses: a 3-year follow-up. *Int J Prosthodont* 2009;22:553–60.

- [18] Schwarz S, Schröder C, Hassel A, Bömicke W, Rammelsberg P. Survival and chipping of zirconia-based and metal-ceramic implant-supported single crowns. *Clin Implant Dent Relat Res* 2012;14:e119–25.
- [19] Spies BC, Stampf S, Kohal J. Evaluation of zirconia-based all-ceramic single crowns and fixed dental prosthesis on zirconia implants: 5-year results of a prospective cohort study. *Clin Implant Dent Relat Res* 2015;17:1014–28.
- [20] Viennot S, Dalard F, Lissac M, Grosogeat B. Corrosion resistance of cobalt-chromium and palladium–silver alloys used in fixed prosthetic restorations. *Eur J Oral Sci* 2005;113:90–5.
- [21] Garoushi S, Vallittu PK. Chairside fabricated fiber-reinforced composite fixed partial denture. *Libyan J Med* 2007;2:40–2.
- [22] Van Heumen CC, Kreulen CM, Creugers NH. Clinical studies of fiber-reinforced resin-bonded fixed partial dentures: a systematic review. *Eur J Oral Sci* 2009;117:1–6.
- [23] Başaran EG, Ayna E, Vallittu PK, Lassila LV. Load bearing capacity of fiber-reinforced and unreinforced composite resin CAD/CAM-fabricated fixed dental prostheses. *J Prosthet Dent* 2013;109:88–94.
- [24] Bonfante EA, Suzuki M, Carvalho RM, Hirata R, Lubelski W, Bonfante G, et al. Digitally produced fiber-reinforced composite substructures for three-unit implant-supported fixed dental prostheses. *Int J Oral Maxillofac Implants* 2015;30:321–9.
- [25] Oikarinen K, Raustia AM, Hartikainen M. General and local contraindications for endosseal implants – an epidemiological panoramic radiograph study in 65-year-old subjects. *Community Dent Oral Epidemiol* 1995;23:114–8.
- [26] Esposito M, Hirsch JM, Lekholm U, Thomsen P. Biological factors contributing to failures of osseointegrated oral implants. (II). Etiopathogenesis. *Eur J Oral Sci* 1998;106:721–64.
- [27] Noda K, Arakawa H, Kimura-Ono A, Yamazaki S, Hara ES, Sonoyama W, et al. A longitudinal retrospective study of the analysis of the risk factors of implant failure by the application of generalized estimating equations. *J Prosthodont Res* 2015;59:178–84.
- [28] Esposito M, Grusovin MG, Felice P, Karatzopoulos G, Worthington HV, Coulthard P. The efficacy of horizontal and vertical bone augmentation procedures for dental implants—a cochrane systematic review. *Eur J Oral Implantol* 2009;2:167–84.
- [29] Satoh T, Maeda Y, Komiyama Y. Biomechanical rationale for intentionally inclined implants in the posterior mandible using 3D finite element analysis. *Int J Oral Maxillofac Implants* 2005;20:533–9.
- [30] Las Casas EB, Ferreira PC, Cimini Jr. CA, Toledo EM, Barra LP, Cruz M. Comparative 3D finite element stress analysis of straight and angled wedge-shaped implant designs. *Int J Oral Maxillofac Implants* 2008;23:215–25.
- [31] Bonnet AS, Postaire M, Lipinski P. Biomechanical study of mandible bone supporting a four-implant retained bridge: finite element analysis of the influence of bone anisotropy and foodstuff position. *Med Eng Phys* 2009;31:806–15.
- [32] Geris L, Vandamme K, Naert I, Vander Sloten J, Van Oosterwyck H, Duyck J. Mechanical loading affects angiogenesis and osteogenesis in an in vivo bone chamber: a modeling study. *Tissue Eng Part A* 2010;16:3353–61.
- [33] Davies JE. Understanding peri-implant endosseous healing. *J Dent Educ* 2003;67:932–49.
- [34] Leonard G, Coelho P, Polyzois I, Stassen L, Claffey N. A study of the bone healing kinetics of plateau versus screw root design titanium dental implants. *Clin Oral Implants Res* 2009;20:232–9.
- [35] Erkmén E, Meriç G, Kurt A, Tunç Y, Eser A. Biomechanical comparison of implant retained fixed partial dentures with fiber reinforced composite versus conventional metal frameworks: a 3D FEA study. *J Mech Behav Biomed Mater* 2011;4:107–16.
- [36] Leinfelder KF. An evaluation of casting alloys used for restorative procedures. *J Am Dent Assoc* 1997;128:37–45.
- [37] Geurtsen W. Biocompatibility of dental casting alloys. *Crit Rev Oral Biol Med* 2002;13:71–84.
- [38] Tai Y, DeLong R, Goodking RJ, Douglas WH. Leaching of nickel, chromium, and beryllium ions from base metal alloy in an artificial oral environment. *J Prosthet Dent* 1992;68:692–7.
- [39] Ardlin BI, Dahl JE, Tibballs JE. Static immersion and irritation tests of dental metalceramic alloys. *Eur J Oral Sci* 2005;113:83–9.
- [40] Al-Hiyasat AS, Bashabsheh OM, Darmani H. Elements released from dental casting alloys and their cytotoxic effects. *Int J Prosthodont* 2002;15:473–8.
- [41] Schmalz G, Garhammer P. Biological interactions of dental cast alloys with oral tissues. *Dent Mater* 2002;18:396–406.
- [42] Hensten-Pettersen A. Casting alloys: side-effects. *Adv Dent Res* 1992;6:38–43.