

Minimally invasive implant dentistry with short or narrow implants

Ridge splitting and crestal and internal sinus lift

Prof. Mauro Marincola¹, Dr Daniel Hernández-González¹, Dr Jaime Guzmán-De Ávila¹ & Dr Miguel Simancas-Pallares¹, Colombia

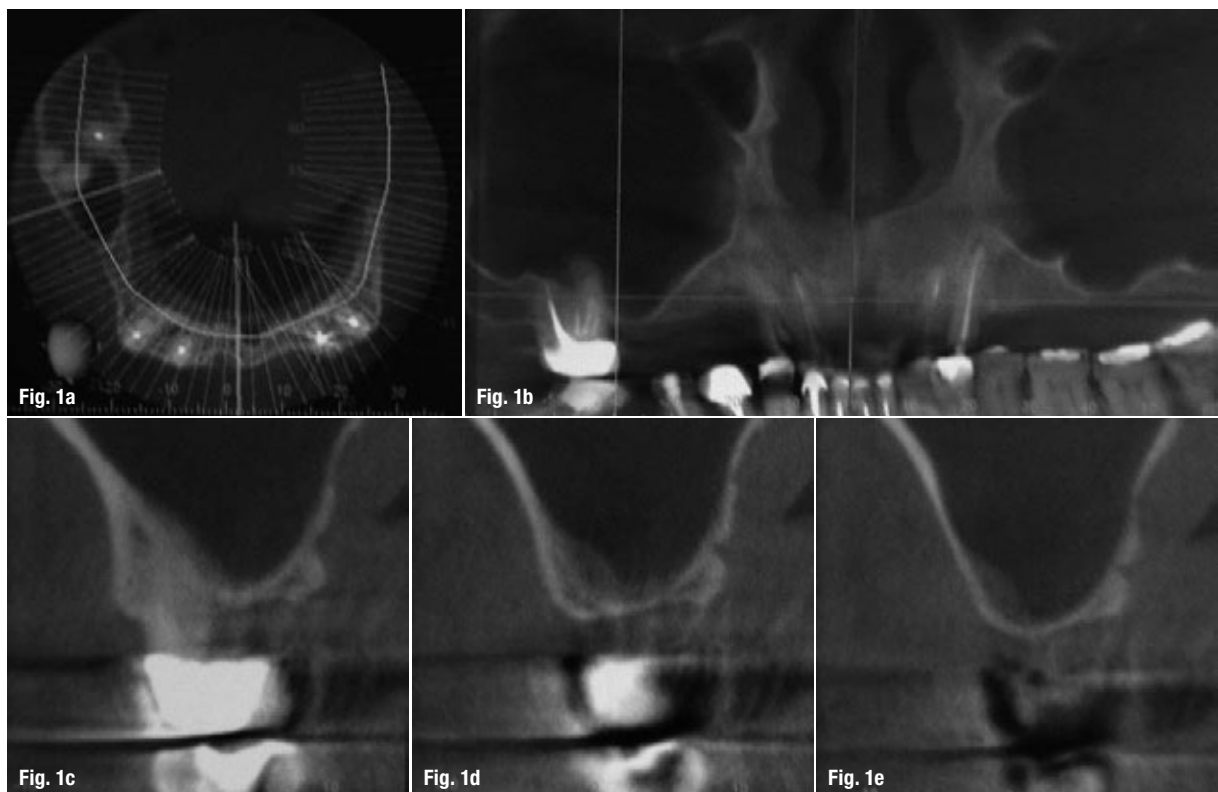
¹Dental Implant Unit, Faculty of Dentistry, University of Cartagena, Colombia

Introduction

Dental implants have been advocated as the treatment of choice for missing teeth and tooth replacements. Scientific evidence demonstrates their high success rates and therefore their clinical applicability. However, in some circumstances due to premature posterior tooth loss leading to severe sinus pneumatization or a congenitally missed tooth causing alveolar bone collapse, implant placement can still remain challenging for clinicians. These circumstances could be present in one surgical

target area at the same time, thus increasing treatment complexity. In such cases, available options such as short implants, ridge splitting, and internal and crestal sinus lifts have been proposed to minimise treatment cost and time, as well as co-morbidities but preserve treatment success rates.

In order to address clinical-related sinus pneumatization issues, two main surgical approaches have been suggested: internal and lateral sinus lift techniques. The internal sinus lift approach is indicated whenever the re-



Figs. 1a–e: CT scan analysis of the targeted surgical area: **a)** Coronal view of the maxilla showing the limited width and **b)** panoramic view of the maxilla depicting the reduced vertical bone height in the right quadrant. **c–e)** Sagittal views of the molar area with the diminished residual bone height as little as 1 mm.

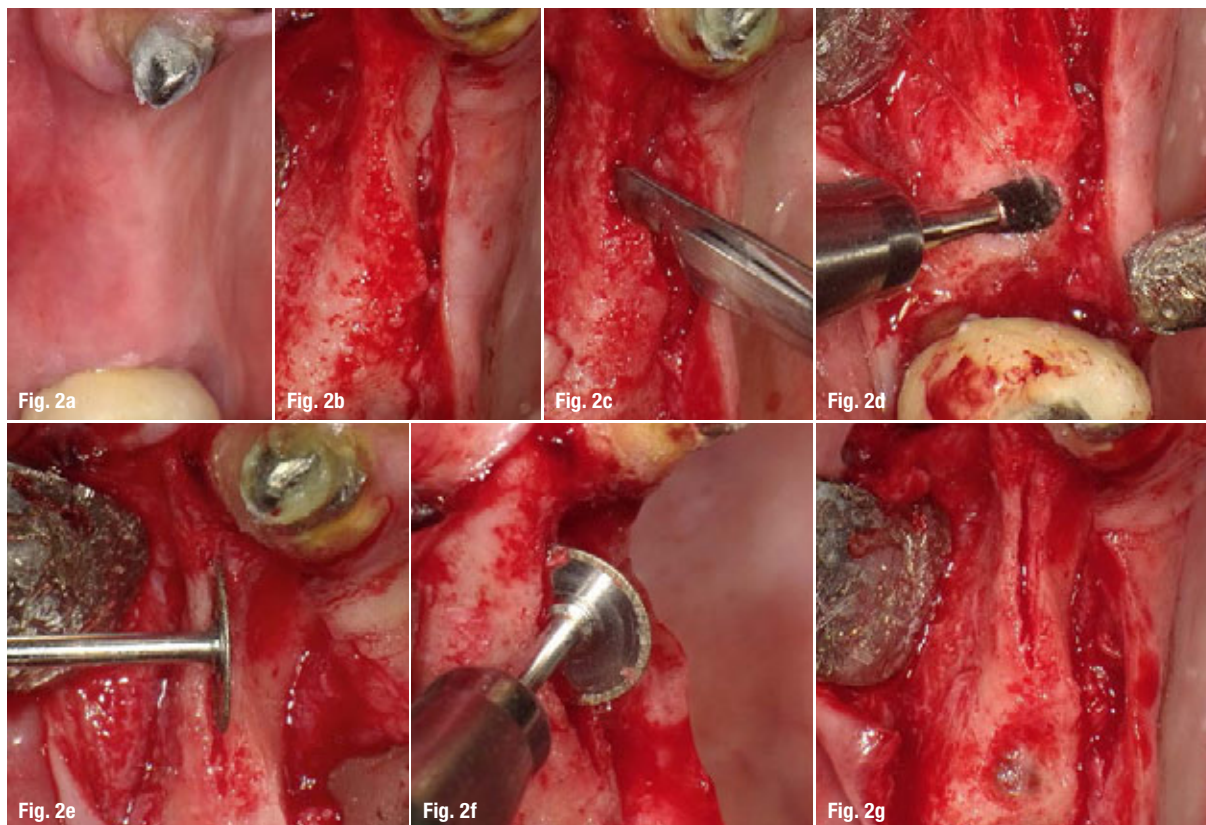


Fig. 2a: Pre-op view of the targeted surgical area. **Fig. 2b:** Targeted surgical area once the full-thickness flap was obtained. **Fig. 2c:** Cortical perforations to generate initial split. **Fig. 2d:** Crestal perforation in order to expose the sinus cortical bone and perform a sinus lift. **Figs. 2e & f:** Cortical deepening by use of a diamond-covered disc under continuous irrigation. **Fig. 2g:** Surgical view of the split area in the premolar zone and the crestal perforation in the molar area.

residual bone height (RBH) is 4 to 7 mm. First proposed by Summers, it entails performing a cortical greenstick fracture using osteotomes, allowing the Schneiderian membrane to be easily lifted.¹ This technique has the advantage of allowing immediate implant insertion. The lateral sinus lift approach is suggested when the RBH is less than 4 mm. With this skill-dependent technique, a bony lateral window has to be created, exposing the cortical bone. Once this has been achieved, membrane detachment with the use of curettes is performed, and an alloplastic material is injected as a bone graft. After a graft healing period of five to six months, the implants can be inserted. In order to address alveolar collapse issues, ridge splitting was proposed as a surgical approach, wherein the cortical plates are separated to allow the insertion of implants into the artificially created space.

All these options are of high clinical value when facing such scenarios. However, implant length is considered one of the most important predictors in treatment efficacy when performing these techniques. Likewise, short implants have been proposed, since they have marked clinical advantages, such as minimising the amount of sinus membrane to be lifted and grafting material to be injected, thus introducing the concept of minimally invasive implant dentistry. Short implants are widely dis-

cussed because of their increased use in recent years. Historically, long implants (> 13 mm) in combination with sinus lift procedures were recommended to restore function and aesthetics. Nowadays, improvement on implant design and scientific evidence have shown high success/survival rates of short implants, thus indicating them to be among the most valuable approaches in modern dentistry.

Having all these concepts in mind, the objective of this case report was to demonstrate the use of short implants in combination with ridge splitting and internal and crestal sinus lift in the same surgical area, thus applying a minimally invasive dentistry approach.

Case presentation

A 52-year-old male patient consulted our practice owing to his desire for functional and aesthetic restoration. The patient did not report any medical background of dental interest. He also signed informed consent prior to the start of treatment and was classified as ASA I physical status. After radiographic (Figs. 1a–e) and clinical (Fig. 2a) examination, it was found that the patient required dental implantation in the right posterior maxilla owing to the missing first and second premolars and first molar.

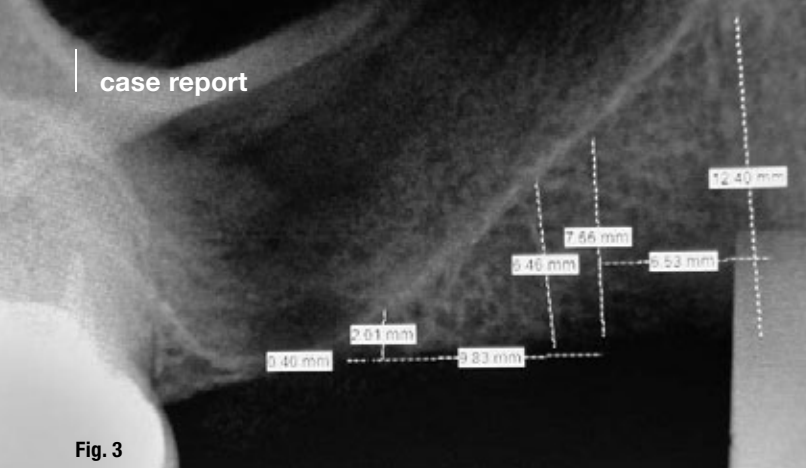


Fig. 3

Fig. 3: Residual bone height analysis in the targeted surgical area showed 12.40 mm in the first premolar area, 6.46 mm in the second premolar area and 0.40 mm in the molar area.

Amoxicillin (500 mg every 8 hours) was prescribed two days before the surgical procedure in order to avoid infections. An experienced clinician then performed the surgical treatment as follows:

1. First premolar: ridge splitting with simultaneous insertion of a narrow implant.
2. Second premolar: ridge splitting, internal sinus lift with simultaneous insertion of a narrow implant.
3. First molar: crestal sinus lift with simultaneous insertion of a short implant.

Surgical technique

Infiltrative anaesthesia was performed during the entire procedure. Initially, a non-adrenaline anaesthetic was used (PRICANEST 4%, Ropsohn Therapeutics, Colombia) in order to collect blood to mix with a grafting material (50–500 µm SynthoGraft, Bicon Dental Implants, USA). Then, 2% Xylocaine (Dentsply Pharmaceutical, USA) was used to complete the surgical treatment.

Using a #15 blade in a Bard-Parker scalpel, we performed an intrasulcular incision. A full-thickness flap was obtained in the area and then using the blade edges and surgical mallet, cortical perforations were performed covering the premolar area (Figs. 2b & c). Using a carbide round-edge bur (Sinus Lift Bur, Bicon Dental Implants) on a low-speed handpiece, we created a crestal—but not lateral—window until the sinus cortical bone was clearly exposed (Fig. 2d). Then, using a diamond-covered disc (Frios MicroSaw Diamond Discs, Dentsply Sirona, USA) on a low-speed handpiece, we achieved a deeper cortical split in the premolar area (Figs. 2e–g).

A digital radiograph (Dr Suni, Suni Medical Imaging, USA) with a surgical chisel inserted was performed to

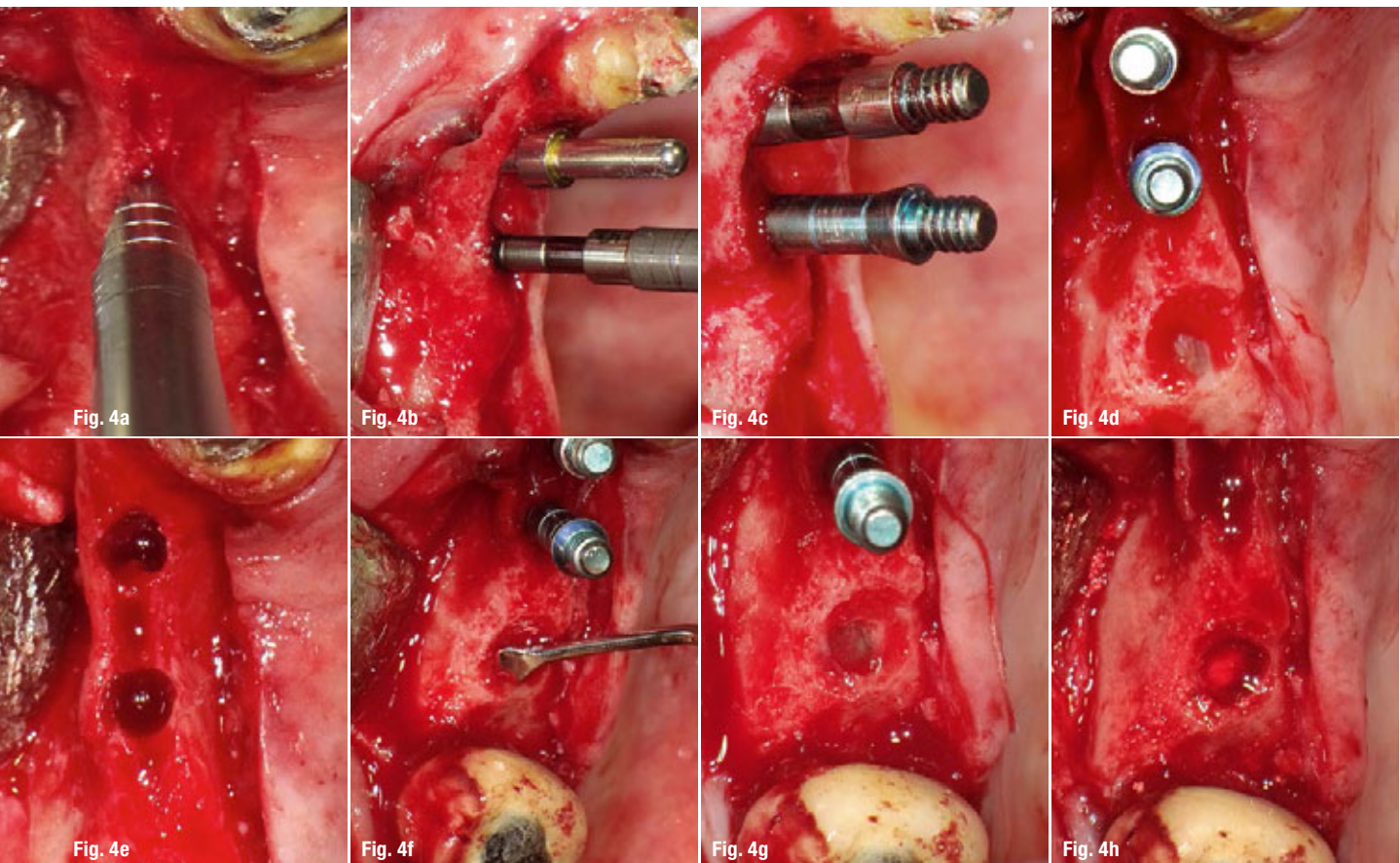


Fig. 4a: Use of surgical chisels to create the artificial space (split) for implant insertion. **Fig. 4b:** Split area with hand reamers and paralleling pin. **Figs. 4c & d:** Split area with hand reamers. **Fig. 4e:** Prepared space to receive implant insertion. **Fig. 4f:** Schneiderian membrane lift using surgical curettes. **Figs. 4g & h:** Lifted membrane and grafted space.

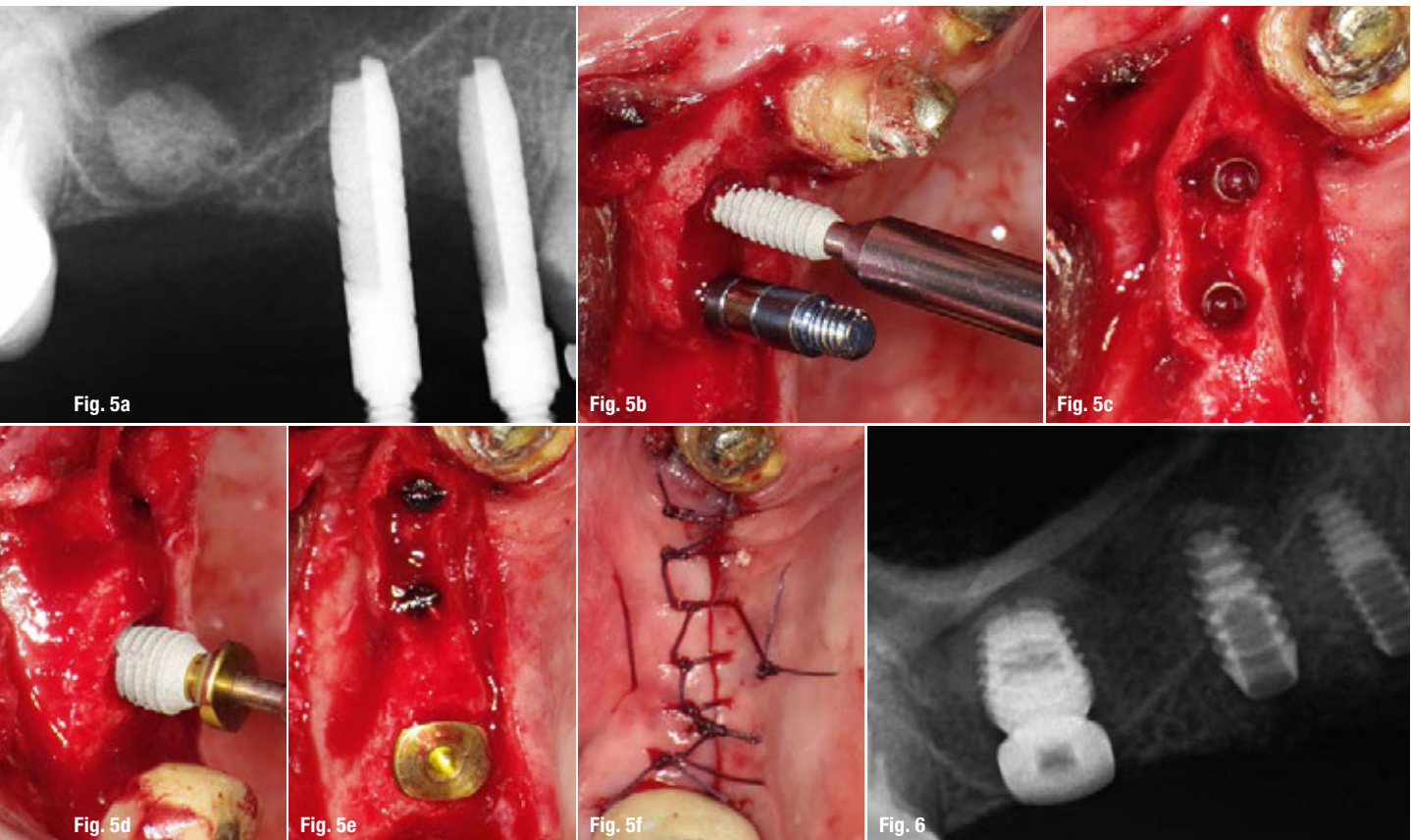


Fig. 5a: Periapical radiograph showing the hand reamers in the premolar area and the grafting material in the molar area. **Fig. 5b:** Insertion of narrow implant in the first premolar space. **Fig. 5c:** Inserted narrow implants in the split premolar area. **Fig. 5d:** Insertion of a short implant with a sinus lift abutment in the molar area. **Fig. 5e:** Two narrow implants (premolar area) and the short implant (molar area) inserted in the targeted surgical area. **Fig. 5f:** Sutured wound using the continuous technique. **Fig. 6:** Immediate post-op radiograph.

control RBH (Fig. 3). Surgical chisels were employed to increase length and width in the split area (Fig. 4a). Figures 4b–e show the subsequent use of hand reamers to create the implant space. Besides the ridge split procedure, in the area of the second premolar, a previously published protocol was followed in order to simultaneously perform the sinus lift.²

For the molar area, surgical curettes were used to carefully lift the Schneiderian membrane (Fig. 4f). A synthetic and bacteriostatic grafting material (SynthoGraft; beta-tricalcium phosphate, size 50–500µm) was mixed with the collected blood to a putty consistency—no liquid was evident in the mixture. Then, a 4 mm bone graft syringe was used to place a bone graft material into the apical portion of the osteotomy. Once resistance against the Schneiderian membrane was detected, the syringe was slowly retracted while continuously injecting (Figs. 4g & h). A new digital periapical radiograph was taken to control the grafted space and premolar osteotomies (Fig. 5a). In the first and second premolar areas, one 3.0x8.0mm implant and one 3.5x8.0mm implant (Bicon Dental Implants) were inserted, respectively, with the use of seating tips (Figs. 5b & c).

After bone grafting material had been injected, a 4.5x6.0mm implant (Bicon Dental Implants) was inserted into the lifted sinus using an implant inserter-retriever mounted in a straight handle at first and then gently tapping with a seating tip. Owing to the limited RBH in the area (Fig. 3), a sinus lift abutment (Bicon Dental Implants) was used in conjunction with the implant in order to avoid implant displacement into the lifted grafted space (Figs. 5d & e).

Finally, a continuous suture with polyglycolic acid was used to close the incisions (ACE Surgical Supply, USA; Fig. 5f). After implant insertion, an immediate postoperative radiograph was taken (Fig. 6). The patient received postoperative and home care instructions. An antibiotic (amoxicillin) and analgesic (ibuprofen) were prescribed in order to avoid infection, pain or swelling.

Discussion

Several research results have shown the successful outcomes of using surgical procedures such as ridge splitting and sinus lifts in combination with or without dental implants. Brizuela et al. evaluated 36 threaded im-

plants in 36 patients placed using internal sinus lift without grafting material and showed after 24 months that the implant success rate was 91.6 per cent.³ Further, Nedir et al. showed that atrophic posterior maxillae could be predictably rehabilitated using osteotomes with simultaneous implant placement.⁴ The new bone formed around implants after one year was stable after five years, irrespective of the presence or the absence of a graft.⁴ Grafting was unnecessary to achieve an average bone augmentation of 3.8 mm, but more bone was gained with grafting.⁴ Deliberador et al. successfully demonstrated the use of the ridge split technique with simultaneous implant insertion.⁵

Despite all of these results, there is little in the scientific literature on a combination of procedures, for example sinus lift and ridge splitting, and implant insertion, as shown in this case report. In this patient, the second premolar area was effectively regained using the ridge split and internal sinus lift techniques in the same surgery.

The literature is conclusive that internal sinus lift should be performed when the available RBH is between 4 mm and 7 mm and lateral sinus lift whenever an RBH of less than 4 mm is present. This case report successfully describes the use of an innovative surgical approach (crestal sinus lift) too via the bone crest lift of the maxillary sinus when the available RBH was less than 1 mm. This approach represents less morbidity and greater time saving and allows implant placement in the same surgery thus decreasing overall treatment time.

Schiegnitz et al. found that evaluation of oral health-related quality of life after sinus augmentation showed significant improvement, indicating a remarkable benefit of this procedure for patients.⁶ Nevertheless, we need additional studies, such as randomised controlled trials, to properly demonstrate effectiveness of these innovative techniques. Tallarico et al. described a crestal approach to sinus lift, showing that sinus floor augmentation can be successfully accomplished with a transcresal ap-

proach using a dedicated implant system.⁷ However, in this study, the mean initial RBH was 4.64 ± 0.86 mm, which is more consistent with the internal sinus lift and not the crestal sinus lift surgical indications.

Performing ridge splitting, combined ridge splitting and internal sinus lift, and crestal sinus lift with simultaneous insertion of a short or narrow implant in the same patient constitutes a minimally invasive implant dentistry approach, since they are less time-consuming procedures and produce a minimum rate of complications that represents a less traumatic surgical approach.

Editorial note: The authors disclosed that they have no conflict of interest and that they received no funding for this article.



contact

Dr Miguel Simancas-Pallares

Dental Research Department
Faculty of Dentistry
University of Cartagena
Avenida Del Consulado 48-152,
Cartagena 130014, Bolívar, Colombia
Phone: +57 5 6698172-110
msimancasp@unicartagena.edu.co