

# TRINIA™

## Metal-free restorations

**Authors:** Prof. Dr Dr Rolf Ewers, Paolo Perpetuini, Dr Vincent J. Morgan, Prof. Dr Mauro Marincola, Richard Wu & PD DI Dr Rudolf Seemann, Austria/Italy/USA



### Introduction

There are several reasons not to use dental restorations made of metal. Possible disadvantages of metal are for instance the potential allergenicity (type IV allergy) and weight, density, as well as the long processing time. Furthermore, the colour of metals differs visibly from gingiva and teeth. Metal has in fact a great strength, but it is, however, much harder than the natural tooth. Metals are very good thermal conductors and isolate from temperature much worse than teeth. Every patient with deep fillings or cast gold inlays probably knows about these properties.

For the named reasons, the problematic aesthetics of metals and their alloys as well as their mechanical properties, the search for other materials has not ended yet. Furthermore, allergological and biological concerns of patients and doctors have gained more importance in the last years.

TRINIA™ was developed to provide dentists with CAD/CAM-milled metal-free restorations.

This report presents TRINIA™, a metal-free fibre-reinforced CAD/CAM material. Due to its flexural strength, it is comparable to dentin and simulates the function of Sharpey's fibres. Its properties provided excellent results for 101 bridges and full-arch prostheses in a period of up to 64 months with very little complications. The following case presentations demonstrate the elegant CAD/CAM planning and milling procedures for difficult situations like the treatment of extremely severe maxillary and mandibular atrophy (class VI). The concurrence of the flexural strength of TRINIA™ and the attributes of the short Bicon implants provided successful results for our treatment of atrophic maxillae and mandibles with minimal implant losses and 100 per cent successful full-arch TRINIA™ prosthetic treatments.

### Material properties

TRINIA™ CAD/CAM discs and blocks (Fig. 1) are composed of multidirectional interlacings of fibre-glass and resin in several layers.<sup>1</sup> In addition to the advantage of being a lightweight, TRINIA™ has great

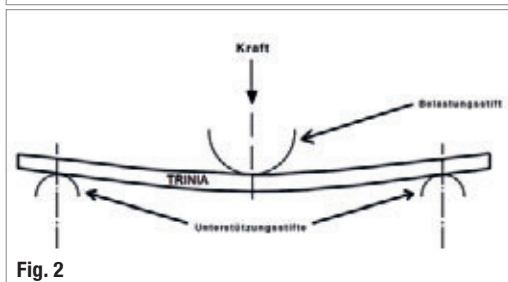
**Fig. 1:** TRINIA™ products.

**Fig. 2:** Setup for measuring flexural strength.

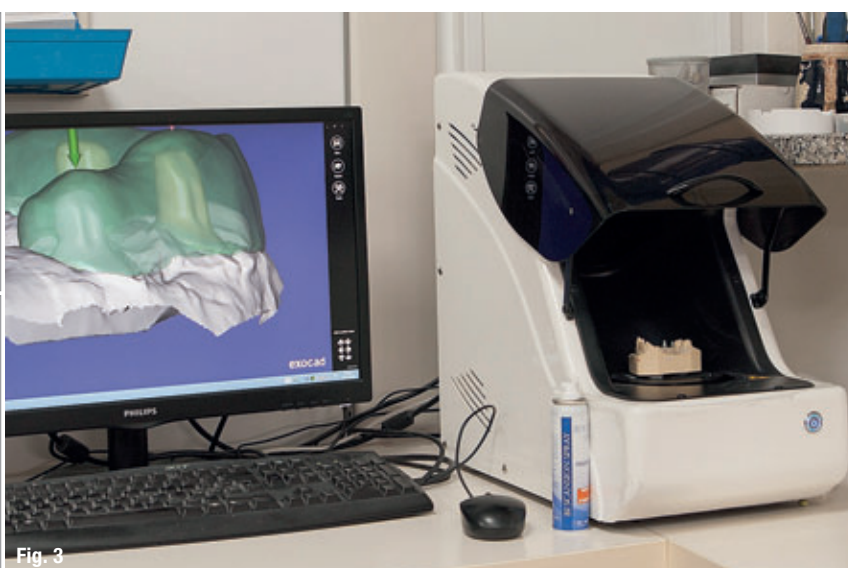
**Fig. 3:** CAD-based planning.



**Fig. 1**



**Fig. 2**



**Fig. 3**



Fig. 4a




Fig. 4b

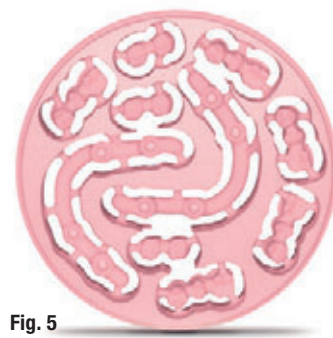

Fig. 5

flexural strength and a flexural modulus of elasticity similar to dentin.

The flexural strength is determined by means of the loading device in the classical three-point bending test (Fig. 2). The tested material—in this case TRINIA™—bends under load. As long as the material does not deform under load, i. e. returns to its original form when the force declines, it remains within the elastic range. If the acting force exceeds the load limit, the material deforms (plastic range) and breaks in the end. The range when that happens to TRINIA™ is similar to that of dentin. In other words: The flexural modulus of elasticity of TRINIA™ is 18.8 GPa, compared to that of dentin being 12–14 GPa<sup>2</sup> and of titanium being 102–118 GPa.<sup>3,4</sup>

As TRINIA™ features a flexural modulus of elasticity that is comparable to dentin, it will behave similarly. TRINIA™ is an American product for permanent restorations approved by the FDA. Fibre-reinforced composites (FRC) by TRINIA™ are composed of 40 per cent of epoxy resin and 60 per cent of fibreglass. Its most outstanding characteristics are the great elasticity featuring a flexural strength of 390 MPa (N/mm<sup>2</sup>) and very low water adsorption of

0.03 per cent. Because of the high level of resilience of TRINIA™ material, every construction or bridge construction features the so-called buffering, comparable to the effect of Sharpey's fibres. The bond of TRINIA™ and abutments is very stable and reaches 18 MPa with 3M RelyX Unicem 2 Automix and 18.6 MPa with Cera Resin Bond (SHOFU).<sup>5,6</sup>

### TRINIA™ CAD/CAM

The relatively simple design and manufacture of prosthetic constructions using CAD techniques is a good alternative to conventional methods (Fig. 3). TRINIA™ can be machined with customary wet- or dry-milling machine systems using nano-diamond burs (Figs. 4 & 5). TRINIA™ is suitable for making copings, substructures or frameworks for permanent and transitional anterior or posterior crowns, bridge-work, and substructures on natural teeth or implants. TRINIA™ constructions can be used either with cemented or uncemented restorations as well as with screwed or telescopic restorations (Figs. 6 & 7). The versatility of TRINIA™ material permits the use for permanent supply with e.g. inlays, onlays, crowns, bridges, veneers or partials. The material is supplied in ivory and in pink (Fig. 8).

**Figs. 4a & b:** CAM-based milling.  
**Fig. 5:** TRINIA™ disc after milling.

**Fig. 6:** Completed TRINIA™ construction.  
**Fig. 7:** Frontal view on the TRINIA™ prosthesis.  
**Fig. 8:** Palatine view on a completed, TRINIA™ prosthesis.  
**Fig. 9:** Panoramic radiograph of a 59-year-old female.  
**Fig. 10:** Plaster model.  
**Fig. 11:** Caudal view of the completed prosthesis.

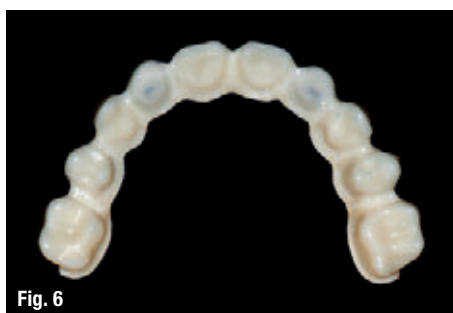

Fig. 6

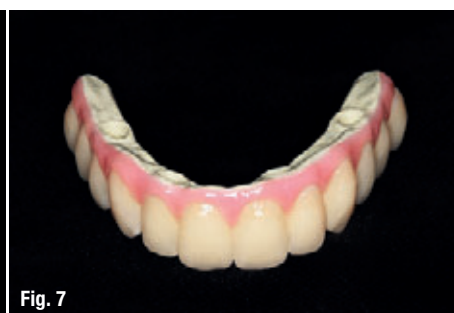

Fig. 7

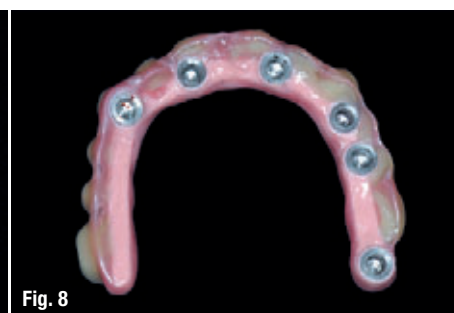

Fig. 8

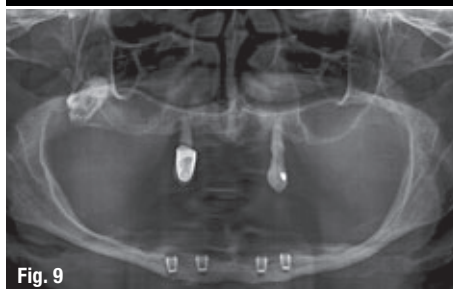

Fig. 9

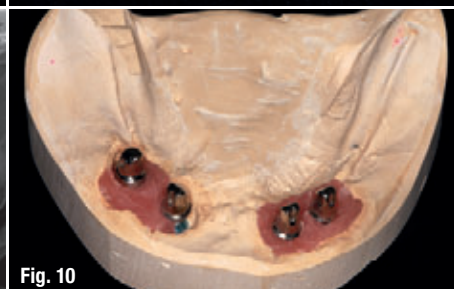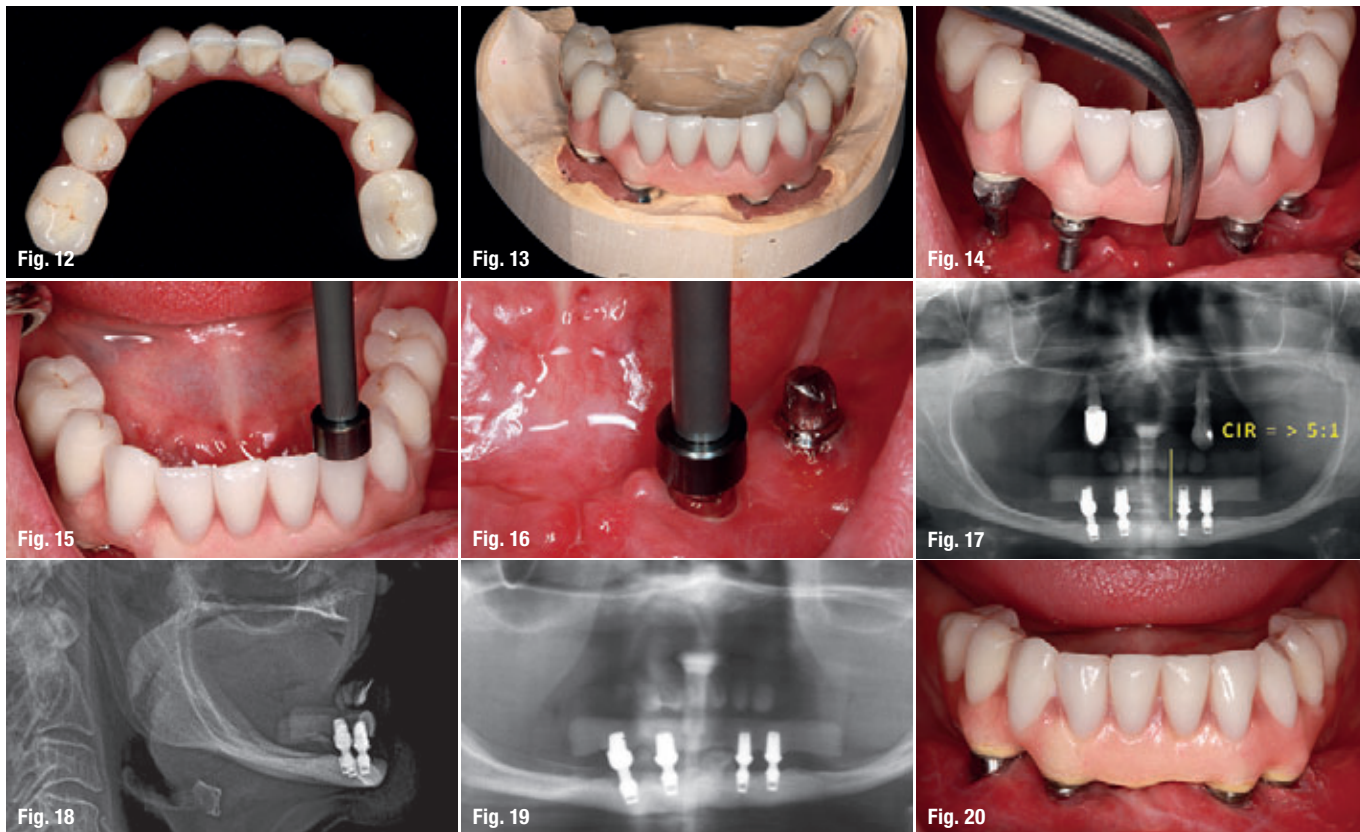


Fig. 10

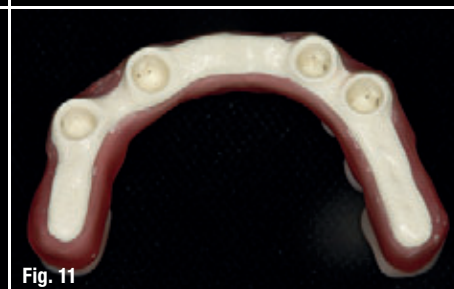

Fig. 11





**Fig. 12:** Cranial view of the completed prosthesis.  
**Fig. 13:** Completed prosthesis in the plaster model.  
**Fig. 14:** Insertion of four abutments in the implant shafts.  
**Fig. 15:** Tapping the abutments in the prosthesis.  
**Fig. 16:** Final tapping of the abutments, resulting in cold shut.  
**Fig. 17:** Panoramic view with inserted abutments and prosthesis.  
**Fig. 18:** Lateral cephalometric radiography.  
**Fig. 19:** Panoramic view at the control after 51 months.  
**Fig. 20:** Intraoral image of the mandibular prosthesis after 51 months.

Flexural rigidity and compression strength of TRINIA™ are high despite the minimal CAD/CAM processing time. TRINIA™ can be processed extra-orally as well as intra-orally. Its wearing comfort high excellent thanks to its light weight.

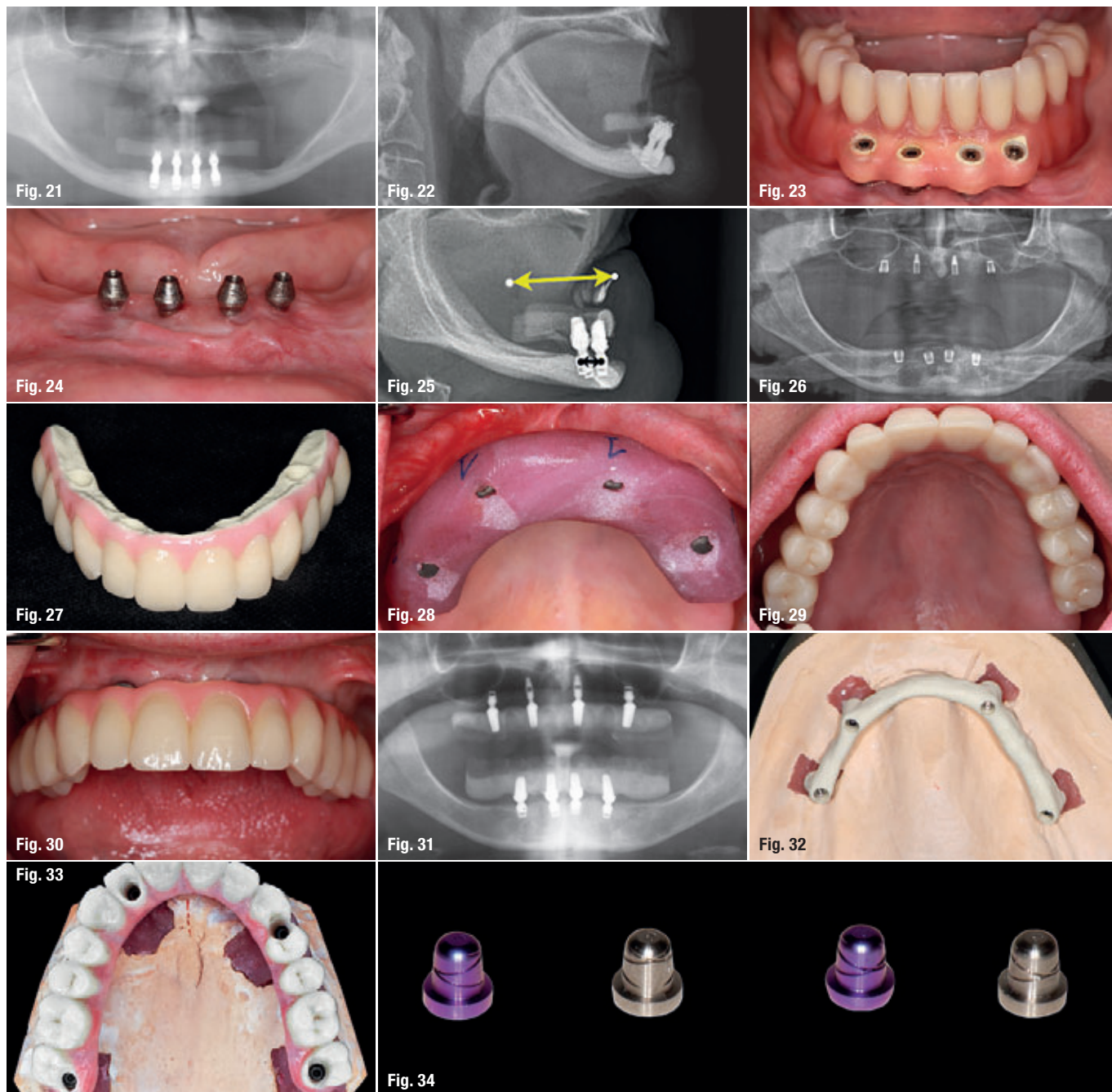
### Case presentation

The cases described in the following represent only a small portion of the possibilities for this material. Figure 9 shows a panoramic radiograph of a 59-year-old female patient with extreme mandibular atrophy class VI according to Cawood and Howell<sup>7</sup> after the insertion of four 4.0x5.0 mm short Bicon implants. After an integration time of three months, the appropriate model can be prepared after exposure and dental imprint (Fig. 10). Then, the ten-piece prosthesis can be manufactured applying the CAD/CAM method (Figs. 11–13). The corresponding implant shafts are found by means of the abutment temporarily fixed with Vaseline in the prosthesis (Fig. 14) and then the abutments are tapped via the prosthesis (Fig. 15). Then, the individual abutments are tapped again to fix them in the implants (Fig. 16). Because the abutment is end-tapered by 1.5 degrees towards the inner shaft, so-called cold welding happens.<sup>8</sup> The panoramic radiograph after the insertion of the cemented bridge illustrates the crown-implant ratio (CIR) of more than 5 : 1 (Fig. 17) and the lateral cephalometric radiography shows pseudoprogenia due to the severely atrophic maxilla

(Fig. 18). The crown-implant ratio of 1 : 1 does not apply to the short Bicon implants anymore.<sup>9–12</sup> Figure 19 shows the panoramic radiograph and figure 20 the clinical image from the follow-up examination 51 months later.

The 59-year-old female patient presented in the following also suffers from distinct mandibular atrophy class VI<sup>7</sup> (Fig. 21). In that case, the four 4.0x5.0 mm short Bicon implants were tilted too far in the labial direction (Fig. 22), so that the prosthesis could be fixed only by means of screwed abutments to be placed in front of the mandibular anterior teeth. This resulted in very long cantilever segments on the distal side of the posterior implants. Despite the extremely heavy load of the TRINIA™ material, it did not break yet even after 64 months of wearing (Figs. 23 & 24).

With our first ten patients with mandibular atrophy class VI<sup>7</sup>, we measured a ratio of 4.3 : 1 from bridge span to implants span for 40 short 4.0x5.0 mm Bicon implants (Fig. 25).<sup>12</sup> With 16 patients treated for atrophic mandibles class VI<sup>7</sup> wearing four 4.0x5.0 mm short Bicon implants, we have lost one implant in the observation period of up to 5.6 years. This corresponds to a survival rate of 98.4 per cent. The patient had lost the left middle implant seven days after the initial treatment, which correlates to implant loss due to lacking osseointegration. Since then, she has been putting the load on the remaining



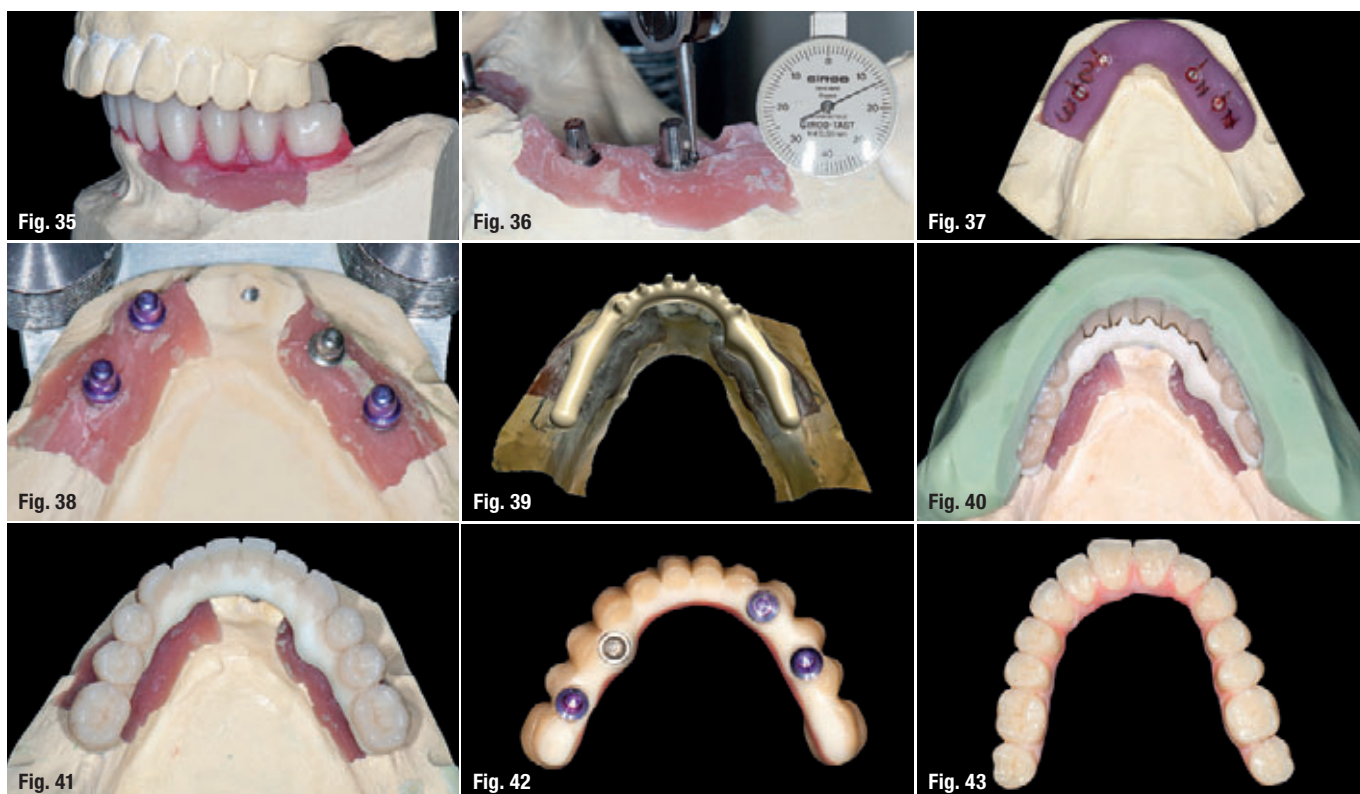
**Fig. 21:** Panoramic view of a 59-year-old female patient with pronounced mandibular atrophy (class VI) after 64 months of wearing the prosthesis. – **Fig. 22:** Lateral cephalometric radiography. – **Fig. 23:** Intraoral view with mandibular prosthesis. The image was taken after 64 months of wearing the prosthesis. – **Fig. 24:** Intraoral view after 64 of wearing the prosthesis. – **Fig. 25:** Lateral cephalometric view. – **Fig. 26:** Panoramic radiograph of a 69-year-old patient with extreme maxillary atrophy (class VI). – **Fig. 27:** Fronto-cranial view of a twelve-piece prosthesis. – **Fig. 28:** Intraoral view of a positioning splint. – **Fig. 29:** Intraoral mirror radiograph of the twelve-piece prosthesis. – **Fig. 30:** Situation after 39 months. – **Fig. 31:** Panoramic radiograph after 39 months of wearing the prosthesis. – **Fig. 32:** Screw-retained TRINIA™ construction on the plaster model. – **Fig. 33:** Twelve-piece screw-retained prosthesis. – **Fig. 34:** Retentive and passive (middle) telescope caps.

three implants of her prosthesis for 47 months. Therefore, the statistics of mandibular prosthetics show 100 per cent success for these 16 patients.

The next 69-year-old patient suffers from extreme maxillary atrophy class VI.<sup>7</sup> In such extreme cases, they used to perform Horseshoe Le Fort I osteotomy using interpositional bone grafts from the iliac crest – a very complex surgery under endotracheal anaesthesia.<sup>13,14</sup> We, in contrast, inserted two 4.0x5.0 mm

short and two 3.0x8.0 mm Bicon implants in a very brief procedure under local anaesthesia (Fig. 26). Twelve-piece TRINIA™ prostheses were integrated in the maxilla too (Fig. 27). To position the abutments easier, you can use a positioning splint made of light-cure GC plastic, on which the dental technician indicates the most favourable insertion sequence for the abutments (Fig. 28). The patients enjoy prosthetics that leave the palate free (Fig. 29). The prosthesis is either cemented, screwed or telescoped via the four





abutments. The follow-up after 39 months resulted in very satisfying radiological and clinical results (Figs. 30 & 31).

The CAD/CAM planning and milling technology facilitate the manufacture of cemented, screwed (Fig. 32 & 33) or standardised copings with two different frictions (retentive or passive, Fig. 34). Meanwhile we supplied 20 patients suffering from atrophic maxilla class VI<sup>7</sup> with 80 implants. We have lost three implants in an observation period of up to 3.2 years. The implant survival rate fell from 98.6 per cent in year one to 93.5 per cent in year three. As these three patients have worn their prosthesis on three implants until the fourth implant was replaced, these again are 100 per cent of prosthetic success.

The following patient demonstration shows the CAD/CAM procedure to manufacture the retentive TRINIA™ telescopic prosthesis. After the first step comprising the setup and clinical evaluation, including the wax fitting (Fig. 35), you need to choose the adequate angular difference of two to three degrees to ensure sufficient friction (Fig. 36). A positioning splint made of light-cure GC plastic helps positioning the abutment (Fig. 37). Three retentive copings suffice for sufficient friction of the telescopic prosthesis (Fig. 38). The next step is the CAD design (Fig. 39). After having manufactured the TRINIA™ framework in the CAM milling procedure, it is positioned between the telescopic copings and the synthetic teeth (Fig. 40) and then the framework

is bonded to the teeth (Fig. 41). Figures 42 & 43 show the finished 12-piece telescopic prosthesis.

In the meantime, we have installed either multi-part bridges or complete prostheses made of TRINIA™ material in altogether 101 patients. In the observation period of 64 months, the material did not chip yet and only one broke.

## Conclusion

The observation period of 64 months for 101 TRINIA™ bridges and prostheses allows the conclusion that this is a method comparable to metal ceramic restorations.

## contact

### Prof. Dr Rolf Ewers

Chairman of CMF Institute Vienna  
Schumanngasse 15  
1180 Vienna, Austria  
rolf@cmf-vienna.com  
www.cmf-vienna.com

### Prof. Dr Mauro Marincola

Via dei Gracchi, 285  
00192 Roma, Italy

### Dr Vincent J. Morgan

DMD/Boston



**Fig. 35:** Setup of the mandibular prosthesis in the articulator.

**Fig. 36:** Measuring the angular difference of two to three degrees in order to achieve adequate friction.

**Fig. 37:** Positioning splint for positioning the abutment (numbers show the sequence of the abutment insertion) with relation to the implant axes.

**Fig. 38:** Only three retentive telescope caps (violet) are necessary for a save retention.

**Fig. 39:** Computer image of the TRINIA™ construction's CAD design.

**Fig. 40:** The milled TRINIA™ construction is positioned between the abutments and the synthetic teeth.

**Fig. 41:** The synthetic teeth are fixed on the TRINIA™ construction.

**Fig. 42:** Caudal view on the completed TRINIA™ prosthesis.

**Fig. 43:** Occlusal view on the completed twelve-piece TRINIA™ prosthesis.