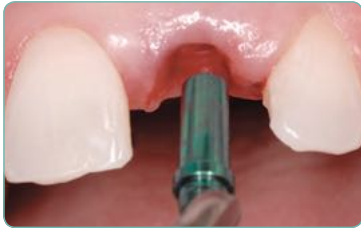
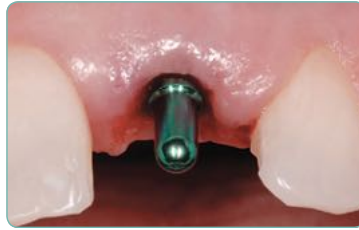
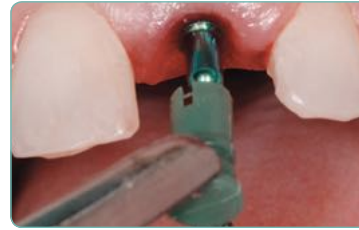**OPTION 1** Implant-Level Impression



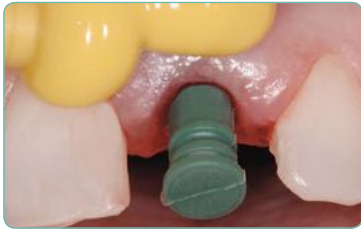**1.** Choose the appropriately sized titanium impression post according to the diameter of the implant well.



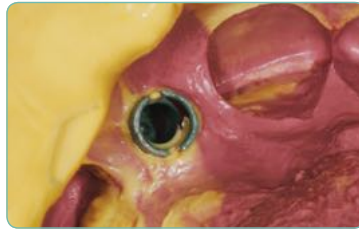**2.** Insert the titanium impression post into the well of the implant with finger pressure only.



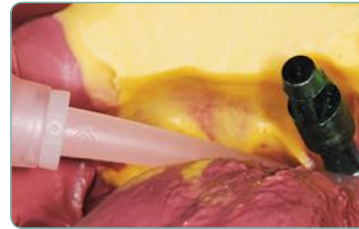**3.** Snap the appropriate impression sleeve onto the impression post.




**4.** Inject impression material around the plastic impression sleeve and make impression.



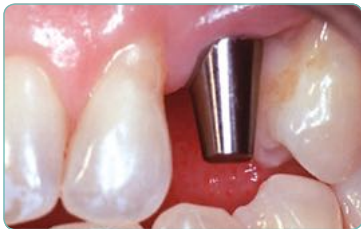**5.** After making the impression, plastic impression sleeve should be withdrawn within the impression while titanium post remains in the implant well.



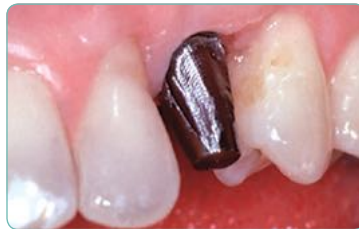**6.** Remove titanium impression post from implant. Assemble the post with the appropriate implant analog. Insert this unit into the plastic sleeve in the impression. Pour soft tissue model. The laboratory technician may now choose the proper abutment for a PFM or IAC restoration.



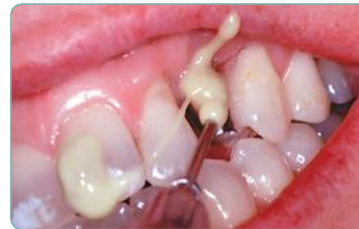**OPTION 2** Direct Abutment Level Impression



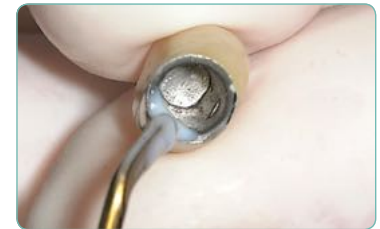**1.** Choose an appropriately sized abutment and definitively seat the abutment with a gentle tapping force.



**2.** The abutment may be modified intra-orally with irrigation or extra-orally with a #1557 carbide bur, if necessary.

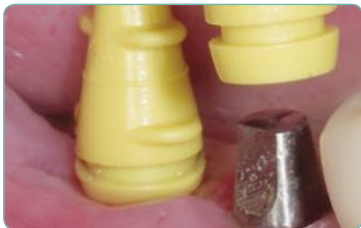

**3.** Inject impression material around abutment for a direct impression. Pour a stone model.

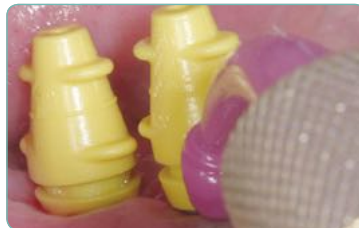

**4.** Fabricate crown conventionally at laboratory. Insert crown with minimal cement.

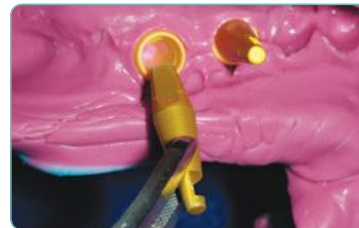
**OPTION 3** Indirect Abutment Level Impression



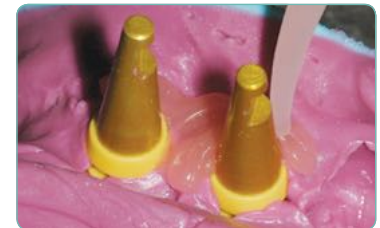**1.** Definitively seat the abutment with a gentle tapping force. Snap impression sleeves onto the unmodified abutment.



**2.** Inject impression material around the impression sleeves and make impression.

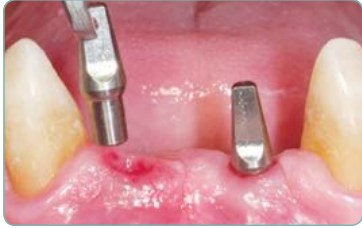

**3.** Withdraw the plastic impression sleeves in the impression. Choose appropriately sized aluminum transfer die and insert the die into the plastic sleeve.

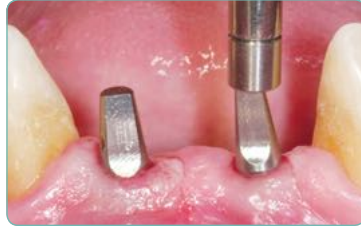

**4.** Pour a soft tissue model. Fabricate crowns conventionally. See Bicon Technique Manuals for further information on this procedure.

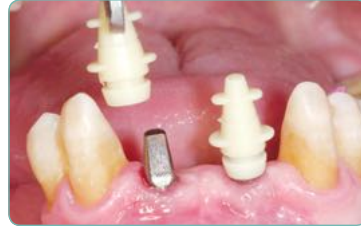**OPTION 1** Transitional Restoration with Sleeve



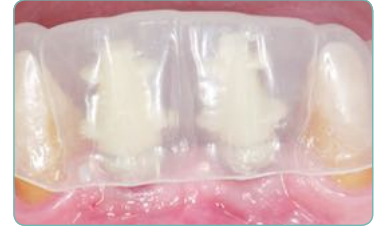**1.** Insert appropriate non-shouldered or stealth shouldered abutment. The diameter of the abutment is dictated by the anatomy of the interdental papillae. The abutment should support the papillae without encroaching upon them.



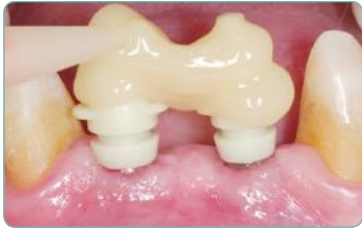**2.** Tap the abutment in the long axis of the abutment post and implant well.



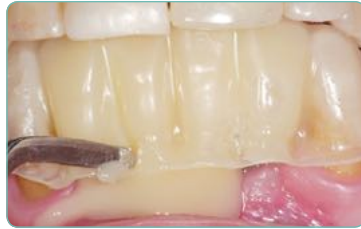**3.** Orientate the internal flat(s) of the appropriate temporization sleeve with the external flat(s) of the abutment prior to snapping it onto the abutment.



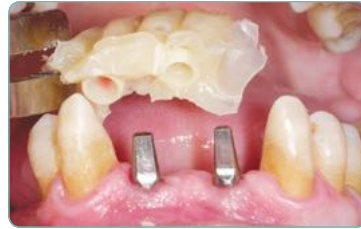**4.** Confirm the appropriateness of the temporization sleeve with a vacuum formed template. Adjust the sleeve as necessary.



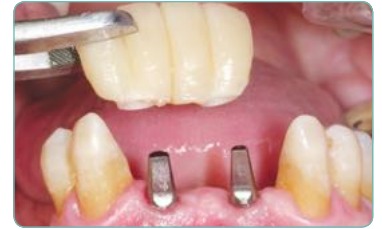**5.** Inject transitional crown material around the temporization sleeve.



**6.** Inject transitional material into the vacuum-formed template prior to re-inserting it over the temporization sleeve to form a transitional prosthesis.

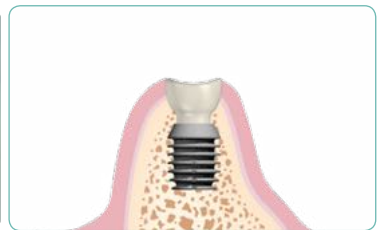
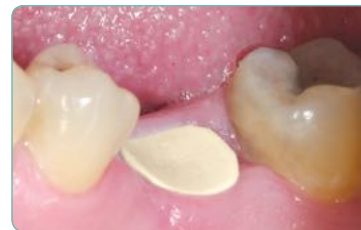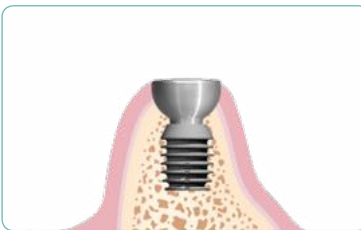

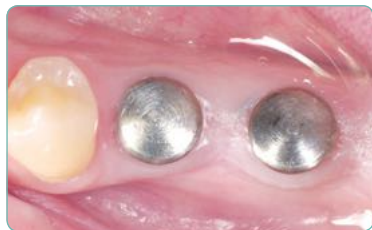
**7.** Remove transitional prosthesis for polishing.




**8.** Snap the completed transitional prosthesis onto the abutment to facilitate the formation and preservation of an aesthetic soft tissue emergence profile.

**OPTION 2** Temporization with a Temporary Abutment

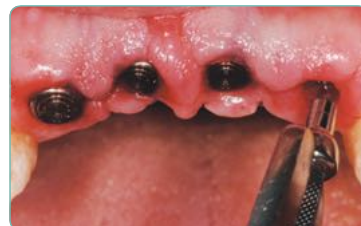

At time of uncovering, place a temporary abutment. The abutment will support the soft tissue and assist in the formation of the gingival sulcus. The abutment may be modified to achieve the desired contour. Transitional crowns should not be placed on temporary abutments. See Bicon catalogs for a complete listing of abutment sizes and shapes that are available.

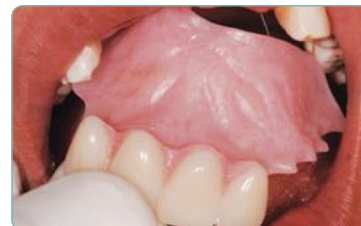**OPTION 3** Transitional Prosthesis in the Aesthetic Zone



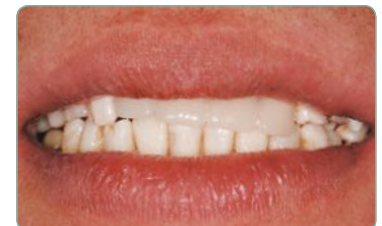**1.** Choose appropriately sized temporary abutment. See Option #2 above.



**2.** Insert temporary abutment into the implant well and gently seat the abutment by tapping on the head of the abutment. Removal of the abutment may be achieved with a variety of extraction forceps.



**3.** In aesthetic areas, a flipper may be inserted for aesthetics and function while tissue is healing around the temporary abutments. See reverse side for the different types of impressions that may be made after the tissue has healed.



**4.** View of inserted provisional restoration.